

## Groin recurrences after surgical and endovascular treatments of varicose veins in the territory of the greater saphenous vein: a coherent hypothesis to explain their occurrence

Massimo Cappelli,<sup>1</sup> Raffaele Molino Lova,<sup>1</sup> Mauro Pinelli,<sup>2</sup> Claude Franceschi<sup>3</sup>

<sup>1</sup>Private practice, Florence, Italy; <sup>2</sup>Private practice, Avezzano (AQ), Italy; <sup>3</sup>Hôpital Saint Joseph, Paris, France

### Abstract

Surgical and endovascular procedures to treat varicose veins in the territory of the Greater Saphenous Vein (GSV) are burdened by a variable rate of groin recurrences. In the case of surgical procedures, they are due to the development of tortuous vessels leading to the formation of a cavernoma in the site of the previous Saphenous-Femoral Junction, after crosssectomy, or to a by-pass of the metallic clip, after crossotomy. In the case of endovascular procedures, groin recurrences are, instead, mainly represented by rectilinear vessels due to the progression of the incompetence within an antigravitational Sapheno-Femoral Junction (SFJ) tributary, most often the Anterior Saphenous Vein (ASV), and rarely by tortuous vessels leading to the formation of a cavernoma in the distal part of the stump always resulting from the procedure. In this paper we suggest a coherent hypothesis to explain the occurrence of groin recurrences after surgical and endovascular procedures based upon experimental studies and observational data. Recurrences due to pelvic shunts or to incompetent thigh perforator veins, are not considered.

**Key words:** groin recurrences, cavernomas, crosssectomy, crossotomy, endovascular procedures.

*Correspondence:* Massimo Cappelli, via Francesco Datini 46, 50126 Florence, Italy. E-mail: [mascappelli@gmail.com](mailto:mascappelli@gmail.com)

### Introduction

Surgical and endovascular treatments of varicose veins in the territory of the Greater Saphenous Vein (GSV) are burdened by a variable rate of groin recurrences that are mainly represented by tortuous vessels, in the case of surgical procedures or by rectilinear vessels in the case of endovascular procedures.

After crosssectomy, recurrences are represented by tortuous vessels that give rise to a nest-shaped tangle of vessels in the site of the previous Saphenous-Femoral Junction (SFJ), known as cavernoma, while after crossotomy,<sup>1,2</sup> recurrences are represented by a tortuous vessel that bypasses the metallic clip, giving the impression that the clip itself has moved. Indeed, although any material can be displaced by scar retraction, in our experience with re-do groin surgery, clips had not moved (see the surgical specimen shown in Figure 1). In the majority of cases, cavernomas are deeply located and show a positive response to the Valsalva maneuver, proving that they are connected with the Deep Venous System (DVS), most often the Common Femoral Vein (CFV). In the remaining few cases, cavernomas are superficially located and show a negative response to the Valsalva maneuver, proving that they are, instead, connected with an SFJ tributary which has been ligated during the crosssectomy: however, over time, even cavernomas showing a negative response to the Valsalva maneuver, may show a positive response. With regard to the by-pass of the clip, they always show a positive response to the Valsalva maneuver,

proving that they are connected with the CFV.

After endovascular procedures, in addition to the possible re-opening of the treated GSV, recurrences are mainly represented by rectilinear vessels due to the progression of the incompetence within an antigravitational SFJ tributary, most often the Anterior Saphenous Vein (ASV), in which the reflux can be instrumentally detected once an ASV re-entry perforator vein has developed. Sometimes, recurrences are represented by tortuous vessels leading to the formation of a cavernoma in the distal part of the stump, which always results from the procedure.

Groin recurrences are commonly believed to result from stumps left by the procedure, either surgical or endovascular, in which a terminal valve, either ostial or parietal, or one or more SFJ tributaries flowing into the stump, may be detected. Further, it is also believed that the longer the stump, the higher the probability of resulting in recurrences. However, some observations seem to challenge the relationship between stumps and recurrences: i) not all the stumps due to SFJ disconnection non-flush with the CFV necessarily result in the development of cavernomas or by-pass of the clip; ii) endovascular procedures always leave a relatively long stump, but not all procedures result in groin recurrences, either rectilinear or tortuous; iii) not all cavernomas, or by-pass of the clip, result from stumps, as a relevant part also results from SFJ disconnections flush with the CFV.

Altogether, the above observations suggest that stumps cannot be all the same. In fact, some stumps, defined as “closed “stumps, show a competent terminal valve and, being protected against the

hemodynamic overload from the CFV by the terminal valve closure, they are stable and do not result in groin recurrences. Other stumps, defined as “open” stumps, show, instead, an incompetent terminal valve, so that they are not protected against the hemodynamic overload from the CFV by the terminal valve closure and, accordingly, they may result in groin recurrences.

Further, the venous wall is fed by an external network of *vasa venarum* represented by an arterial component (*arteriae venarum*) and by a venous component (*venae venarum*), whose drainage may be directed either distally (Figure 2) or proximally (Figure 3) with respect to the SFJ. As the  $pO_2$  of venous blood is low (~40 mmHg), the *vasa venarum* must extend to the sub-endothelial strata to serve their trophic function. Interestingly, Crotty<sup>3</sup> has shown in the dog, whose venous valves are very similar to the human ones, that the network of the *venae venarum* draining the venous wall is connected with the *venae venarum* of the valvular sinuses, and that these last play a relevant role in regulating the tone of the valvular anulus

in response to changes in the Trans-Mural Pressure (TMP) through humoral and neural mechanisms. In fact, in normal conditions, based upon the changes in the TMP, the outlet of these *venae venarum* into the valvular sinuses may be either open or closed, according to the degree of stretching of the endothelial folds of the sinuses that are due to their subendothelial elastic component. The opening of the outlet of the *venae venarum* of the valvular sinuses allows the intraluminal blood to reach the anulus muscles and regulate the tone of the anulus through a noradrenaline-mediated venodilator feedback. In fact, the interaction between plasma noradrenaline and alpha-2 receptors reduces the tone of the anulus muscle by blocking the pre-synaptic sympathetic control.<sup>3,4</sup> On the contrary, when the valve complex is damaged, and, accordingly, its subendothelial elastic component is also damaged, the endothelial folds disappear, resulting in the permanent opening of the *venae venarum* of the valvular sinuses. This might be the fostering condition for the possible occurrence, based upon the intraluminal

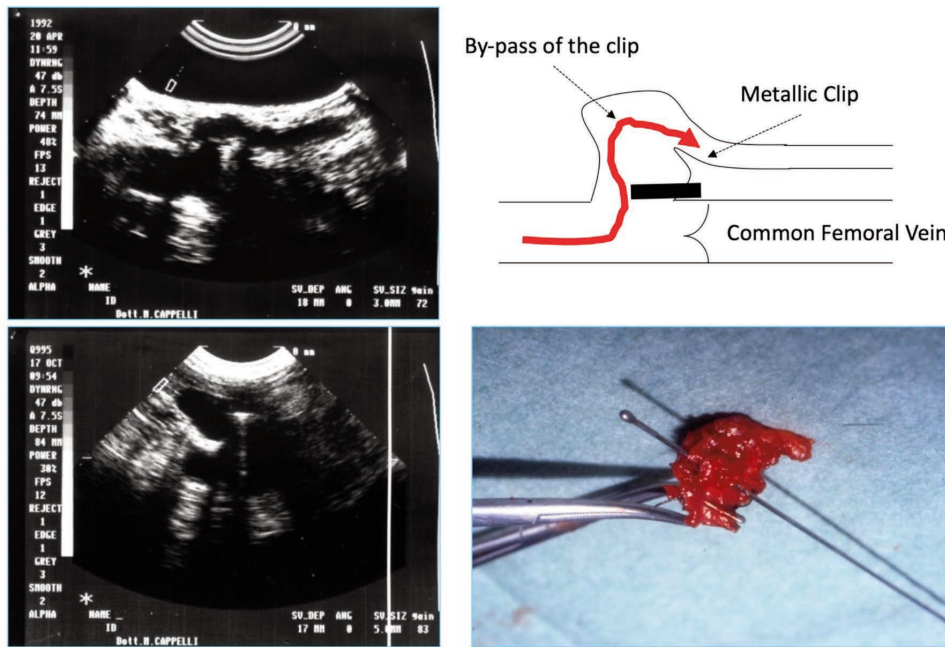


Figure 1. By-pass of the metallic clip giving the misleading impression that the clip itself has moved.

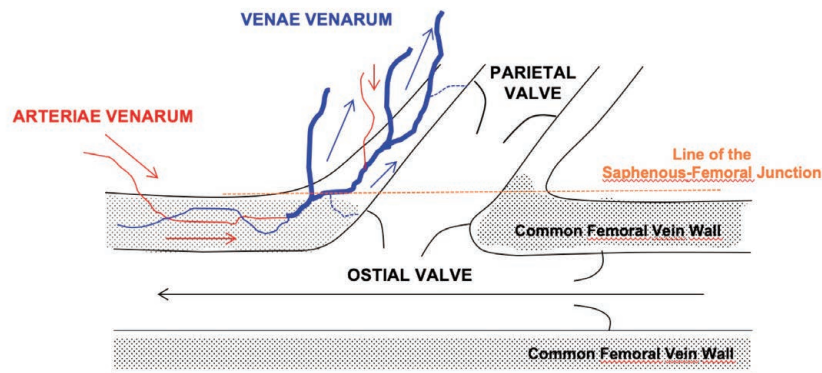


Figure 2. Distal drainage of the perivascular *venae venarum*.

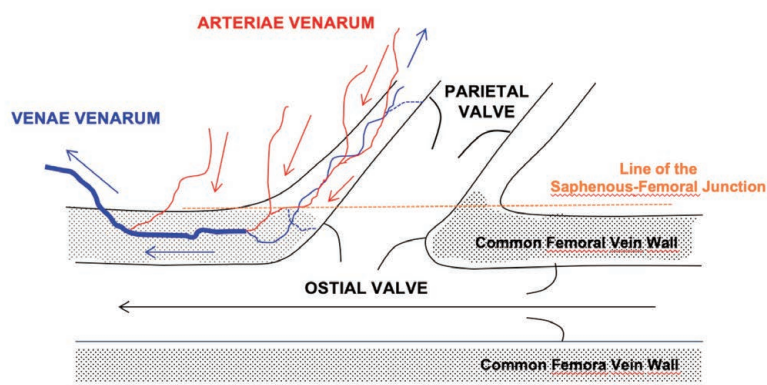
pressure, of a continuous flow directed from inside the lumen of the vein to the external network of the *venae venarum* that drains the venous wall. With regard to human venous valves, Van Cleef *et al.*,<sup>5</sup> by using endoscopy, have documented that, along with the outlets of commissural tributaries, located on the vein's borders and represented by venous branches and perforator veins, human valves also show the outlets of sinusal tributaries, suggesting that they might represent the regulating component of the *venae venarum*. Further, in a study conducted on the perfusion of the venous wall in normal subjects and in subjects with varicose veins by using laser doppler, Belcaro *et al.*<sup>6</sup> have shown that the flux in the normal vein wall is higher than in varicose veins and that after intravenous papaverine injection in the wall of normal veins, there is a significant increase in flux, which is not observed in varicose veins. This also suggests that the *venae venarum* feeding human venous wall might be connected with the regulating *venae venarum* of valvular sinuses. With regard to the SFJ, Tasch and Brenner<sup>7</sup> have shown that the human terminal valve, which, basically, is a hemodynamic concept, when present, can, in terms of anatomy, be either a "marginal" ostial valve (21%), with the muscular component of the anulus being a part of the CFV wall, or a "rearward" valve, with the muscular component of the anulus being a part of the GSV wall. The marginal ostial valve, when present, may be mono-cuspid (5%), bicuspid (6%), or a remnant, (10%); however, independent of the morphology of the marginal ostial valve, when it is present and incompetent, its subendothelial

elastic component is damaged, which fosters the connection between the lumen of the CFV and the perivascular *venae venarum*.

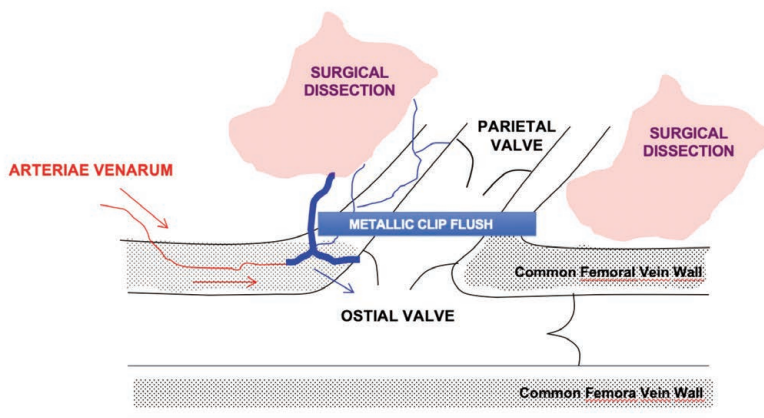
If the drainage of the perivascular *venae venarum* is directed distally with respect to the SFJ (Figure 2), their interruption, due to the surgical dissection, represents an obstacle to their drainage (Figure 4), so that there is an increase in the extra- and intra-parietal pressure of the perivascular *venae venarum*, which further dilates the *venae venarum* flowing into the sinuses. The newly developed vessels within the granulation tissue, resulting from the local production of the Vascular-Endothelial Growth Factor (VEGF), are avaluolated and may join the hypertensive perivascular *venae venarum*, thus creating the bases for the development of a cavernoma or a by-pass of the clip (Figure 5). According to Curri,<sup>8</sup> this represents a case of "true" new-vascularization as the vessels within the granulation tissue were not present before the surgical gesture on the SFJ. If the drainage of the perivascular *venae venarum* is directed proximally (Figure 3), likely the surgical gesture does not affect their drainage, and the probability of developing a cavernoma or a by-pass of the clip is lower.

The abovementioned hypothesis to explain why cavernomas, or by-pass of the clip, may also result from SFJ disconnections flush with the CFV, is supported by personal data (unpublished).

In the very beginning of our experience, from 1990 till 1992, we used to position a metallic clip (Hemoclip Plus 10 Large) parallel and flush with the CFV using a 90-degree angled applicator



**Figure 3.** Proximal drainage of the perivascular *venae venarum*.

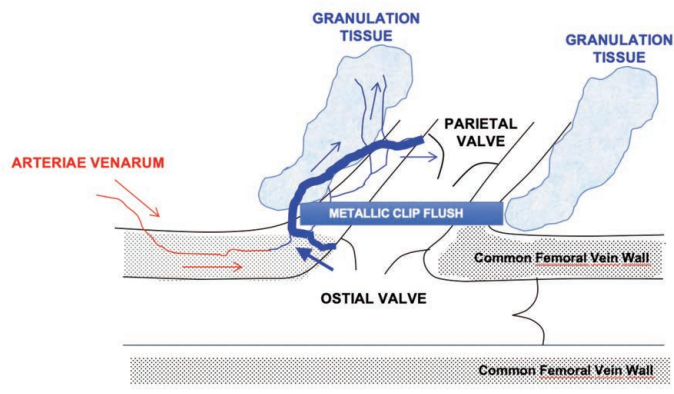


**Figure 4.** The interruption of the perivascular *venae venarum*, due to the surgical dissection, creates an obstacle to the drainage, resulting in intra- and extra-parietal hypertension of the *venae venarum*.

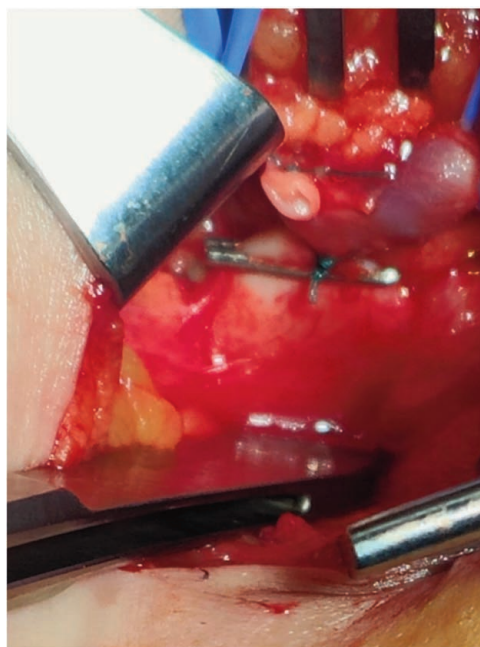
while gently pulling up the GSV stump, in the course of both crossotomy and crossotomy, and over 167 treated SFJs we found 9 (5%) by-pass of the clip. Then, starting from 1993, we have been positioning the clip not only parallel and flush with the CFV, but also pinching the CFV wall (Figure 6), to exclude the valve sinuses, and, consequently, the outlet of *venae venarum* of a potentially present marginal ostial valve into the CFV. We have also been paying special attention not to leave any organic material (fibrous tissue, fat, CFV wall, *etc.*) between the clip extremities, as well as to strongly tighten the clip with the applier and to tighten the tips of the clip with a clamp, as metallic clips lack of a self-locking system, and over 883 crossotomies, we found only 1 (0.1%) by-pass of the clip. To stress the concept that the clip should be positioned actually parallel to the CFV, Figure 7 shows an example in which the clip was not positioned parallel to the CFV, due to the use of a 135-degree angled applier, and, accordingly, failed to exclude both valvular sinuses, which gave rise to a by-pass of the clip on the site

of the valvular sinus not excluded. Surprisingly, in this same time lapse, over 559 crossotomies we found 11 (2%) superficial cavernomas, which suggests that the interruption of SFJ tributaries is also able to trigger the development of cavernomas, in spite of positioning the clip on the CFV wall as in crossotomies.

The ligation of an SFJ tributary causes, in fact, an increase in its internal residual pressure, which is proportional to the flow and, hence, to the caliber. This, in turn, may activate the dilatation of pre-existing vessels (false new-vascularization)<sup>8</sup> belonging to the supra-fascial network, which is a part of the hemodynamic reserve of the venous system, along with the trans- and the sub-fascial network. Further, the increase in the residual pressure in the absence of flow or in the presence of a very slow flow may also trigger an inflammatory process with local production of VEGF that stimulates the development of new vessels (true new-vascularization).<sup>8</sup> Altogether, this fosters the formation of a superficial cavernoma with a negative response to the Valsalva maneuver. This kind of



**Figure 5.** The hypertensive perivascular *venae venarum* join the newly developed vessels within the granulation tissue, resulting in the development of a by-pass of the clip.



**Figure 6.** Positioning of the metallic clip actually pinching the common femoral vein wall.

cavernoma may remain superficial, and give rise to recurrences without an escape point from the deep venous system, or it may join the granulation tissue and the CFV *venae venarum*, creating an intra-parietal venous hypertension. Contrary to deep cavernomas, this intra-parietal venous hypertension originates from outside the CFV and cannot connect with the CFV lumen as the clip positioned on the CFV wall has excluded the outlet of the *venae venarum* of the valve sinuses of a potentially present marginal ostial valve. However, this intra-parietal venous hypertension may trigger an inflammatory process with local production of VEGF, which can lead to the formation of small vascular buds that, given their sub-endothelial location, may “open” into the CFV lumen. As a consequence, the original superficial cavernoma showing a negative response to the Valsalva maneuver may extend in-depth and show a positive response.

With regard to endovascular procedures, the evolution of open stumps towards a rectilinear groin recurrence, *i.e.* towards the descending progression of the incompetence along an antigravitational SFJ tributary, most often the ASV, is related to two pathophysiological mechanisms: the decrease in the Share Stress (SS) and the phasic increase in the TMP.

The decrease in the SS is due to the very slow blood speed within the stump related to the low flow of the gravitational SFJ tributaries that generally show a small caliber. The decrease in the SS is responsible for the leucocyte adhesion to the endothelium, which triggers an inflammatory process involving the venous wall and valves and may result in the descending progression of the ASV incompetence. With regard to the TMP, it is basically increased due to the increase in the stump cross-section (Bernoulli Law). However, TMP also shows a relevant phasic increase due to the systolic impact of the motor energy developed within the CFV that increases the Lateral Pressure (LP) in the stump. Another variable that may affect the stump TMP is represented by the presence of competent valves along the iliac-femoral axis. Actually, they do not fragment the hydrostatic column in the stump, as it is, anyway, connected with the gravitational SFJ tributaries: however, when present, they protect the stump from phasic hypertensive thoraco-abdominal overloads. The increased TMP contributes to the triggering of the inflammatory process, but it is mainly responsible for the structural upheaval of the venous wall and valves that results in the descending progression of ASV incompetence.

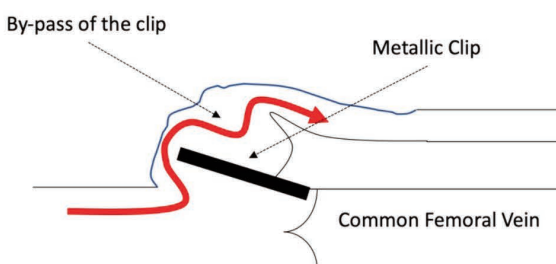
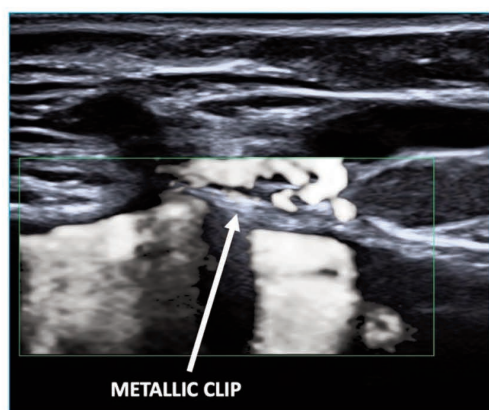
The evolution of open stumps towards the development of cav-

ernomas in the distal part of the stump is less frequent and may be due to the fact that GSV obliteration cannot always be extended till the outlet of the Superficial Epigastric Vein (SEV), for the fear of damaging the SFJ, and this may result in a “secondary” stump within the stump that usually ensues from the procedure. The complete absence of wash-out in the secondary stump, along with the increase in the TMP, triggers an inflammatory process and the local production of the VEGF leads to the formation of new vessels (true new-vascularization).<sup>8</sup> Further, the increase in the TMP also leads to the dilatation of small, invisible, pre-existing vessels (false new-vascularization)<sup>8</sup> if there is a parietal valve close to the outlet of the SEV.

Obviously, endovascular procedures do not result in the formation of granulation tissue in the subcutaneous tissue at the level of the SFJ, as after surgical procedures, so that the development of cavernomas is, anyway, less probable. Further, the descending progression of ASV incompetence is probably quicker than the vessel new-formation, so that the development of cavernomas is less frequent.

Throughout this manuscript, we have involved inflammation in the formation of deep and superficial cavernomas, after SFJ surgery, and in the formation of cavernomas in the distal part of the stump, after endovascular procedures. Interestingly, Bottasso<sup>9,10</sup> has hypothesized the existence of a sympathetic neuroplasticity adaptive mechanism, which would involve the segmental retraction and degeneration of noradrenergic terminals, that are present in most, if not all, vessels and that control wall tone through  $\alpha$ -adrenergic receptors expressed in smooth muscle cells,<sup>11</sup> during the activation of the inflammatory response. However, this hypothesis still needs to be demonstrated, and its meaning in the context of the development of groin recurrences after surgical or endovascular treatments of varicose veins in the GSV territory still needs to be clarified.

In conclusion, with reference to the three challenging observations cited before, those stumps left by surgical or endovascular procedures that do not result in groin recurrences are, most likely, closed stumps. Further, with regard to endovascular procedures, the wash-out of the stump by an SEV showing an adequate flow may limit the occurrence of groin recurrences, even in the case of open stumps. Finally, the exclusion of the *venae venarum* of the valvular sinuses is critical to prevent the occurrence of by-pass of the clip, even in the cases of SFJ disconnection parallel and flush



**Figure 7.** By-pass of the metallic clip due to the non-parallel positioning of the clip.

with the CFV.

Accordingly, the following two suggestions may contribute to mitigating the risk of groin recurrences: i) with regard to surgical conservative procedures, the SFJ should, generally, be treated by crossotomy, *i.e.* the gravitational SFJ tributaries should be left connected to the distal GSV, to avoid the occurrence of superficial cavernomas, and the clip should be positioned not only parallel and flush with the CFV, but should also pinch the CFV wall, to avoid the occurrences of by-pass of the metallic clip; ii) with regard to endovascular procedures, the proximal extension of the obliteration should reach as close as possible to the outlet of the SEV, to avoid resulting in a secondary stump, which is responsible for the occurrence of cavernomas in the distal part of the stump and, probably, an adequate SEV flow, documented by its caliber, together with the presence of a competent valve along the iliac-femoral axis, might also mitigate the risk of the descending progression of the incompetence in the ASV even in the case of open stumps.

---

## References

1. Ricci S. The saphenofemoral junction involvement in the treatment of varicose veins disease. *Veins and Lymphatics* 2017;6:65-73.
2. Cappelli M, Molino-Lova R, Giangrandi I, et al. Ligation of the saphenofemoral junction tributaries as risk factor for groin recurrence. *J Vasc Surg Venous Lymphat Disord* 2018;6:224-9.
3. Crotty TP. The venous valve agger and plasma noradrenaline-mediated venodilator feedback. *Phlebology* 2007;22:116-30.
4. Lee BB, Nicolaides AN, Myers K, et al. Venous hemodynamic changes in lower limb venous disease: the UIP consensus according to scientific evidence. *International Angiology* 2016;35:236-52.
5. Van Cleef JF, Griton PH, Cloarec M, et al. Venous valves and tributary veins. *Phlebology* 1991;6:219-22.
6. Belcaro G, Nicolaides AN, Laurora G, et al. Laser Doppler flux in the venous wall. *Phlebology* 1996;11:68-72.
7. Tasch C, Brenner E. The ostial valve of the great saphenous vein. *Phlebology* 2012;27:179-83.
8. Curri SB. *Le microangiopatie*. Inverni della Beffa, Milano, Italy, 1986.
9. Bottasso E. Toward the existence of a sympathetic neuroplasticity adaptive mechanism influencing the immune response. A hypothetical view – Part I. *Frontiers in Endocrinology* 2019;10:632.
10. Bottasso E. Toward the existence of a sympathetic neuroplasticity adaptive mechanism influencing the immune response. A hypothetical view – Part II. *Frontiers in Endocrinology* 2019;10:633.
11. Jänig W. *Integrative action of the autonomic nervous system. Neurobiology of homeostasis*. Cambridge University Press, Cambridge, UK, 2006.

---

Received: 22 November 2024; Accepted: 14 February 2025; Early view: 13 March 2025.

Contributions: MC and RML conceived the work, drafted the work; MP and CF conceived the work and critically reviewed it for important intellectual content. All the authors have read and approved the final version of the manuscript, and agreed to be held accountable for all aspects of the work.

Conflict of interest: the authors declare no potential conflict of interest.

Funding: none.

Ethics approval and consent to participate: not applicable.

Informed consent: not applicable.

Patient's consent for publication: the patients gave their written consent to use their personal data for the publication of this paper and any accompanying images.

Availability of data and materials: all data generated or analyzed during this study are included in this published article.

*Publisher's note: all claims expressed in this article are solely those of the authors and do not necessarily represent those of their affiliated organizations, or those of the publisher, the editors and the reviewers. Any product that may be evaluated in this article or claim that may be made by its manufacturer is not guaranteed or endorsed by the publisher.*

*This work is licensed under a Creative Commons Attribution-NonCommercial 4.0 International License (CC BY-NC 4.0).*