

Unveiling the uncommon occurrence in an unexplored area: a case report of successfully treated primary upper extremity deep venous thrombosis with a review of the literature

Tammi Raju Iragavarapu, Sahitya Chennapragada, Sushma Vutukuru

Alluri Sitarama Raju Academy of Medical Sciences (ASRAMS), Eluru, India

Abstract

Upper Extremity Deep Vein Thrombosis (UEDVT), though less prevalent than its lower extremity counterpart, poses a substantial risk of morbidity and mortality, particularly among patients in intensive care units. We present a case of Primary Upper Extremity UEDVT in the dominant limb of a 22-year-old female, a software employee. She presented to the hospital with a history of swelling and pain in her right upper limb for 3 months. After several consultations, she sought medical advice at our hospital for her long-lasting symptoms. Doppler study showed a dilated right subclavian vein/ axillary vein with echogenic thrombus, and these vessels are non-compressible. CT venography of the right upper limb confirmed a long segment thrombus in the right subclavian vein from its origin, filling the axillary vein and brachial veins to the level of the upper third of the arm. After excluding all other secondary causes, a diagnosis of primary UEDVT was made. Then, the patient was subsequently started on anticoagulant therapy, and after 3 months of anticoagulation therapy, she was successfully cured of thrombosis. A high index of suspicion is required for early recognition and treatment of UEDVT to prevent complications such as post-thrombotic syndrome, and pulmonary embolism.

Key words: deep vein thrombosis, anticoagulation, upper extremity.

Correspondence: Tammi Raju Iragavarapu, Alluri Sitarama Raju Academy of Medical Sciences (ASRAMS), Eluru, India.
E-mail: vmrtraju.mbbs@gmail.com

Introduction

Upper Extremity Deep Vein Thrombosis (UEDVT) is far less frequent than Lower Extremity Deep Vein Thrombosis (LEDVT). It is about 0.4-1 per 10,000 persons per year but accounts for as much as 10% of all DVT cases.^{1,2} It is often diagnosed late or missed entirely. Primary UEDVT is characterized by compression of the axillary or subclavian vein, leading to blood flow obstruction often associated with thoracic outlet syndrome. The most important risk factors are strenuous muscular exercise and venous flow obstruction due to anatomical variations. Secondary Upper Extremity Deep Vein Thrombosis (UEDVT) is associated with malignancy or the use of intravenous devices such as pacemakers or long-term central venous catheters. It may also be caused by surgery or trauma, blood clotting disorders, indwelling lines, cancer, hormonal therapy use, and sometimes it is idiopathic.³ Pulmonary Embolism (PE) occurs in about 6% of upper extremity DVTs (UEDVT), but asymptomatic PE in these cases can range from 3% to 36%. In contrast, lower extremity DVTs (LEDVT) have a PE incidence of 15-30%. Post-thrombotic syndrome affects fewer than 5% of UEDVT patients when compared to 50% of LEDVT cases.² For UEDVT patients without malignancy, the 3-year survival rate is relatively favourable at 84%. Paget-Schroetter

Syndrome (PSS) or effort thrombosis refers to axillary or subclavian vein thrombosis associated with strenuous, repetitive activity of the upper limb or anatomical abnormalities at thoracic outlet, a rare variant of thoracic outlet syndrome, requires early intervention to prevent the formation of DVT in the upper limbs.⁴

Case Report

A 22-year-old female patient, employed as a software professional, presented to the Department of Cardiology with a history of pain and swelling in her right upper limb for 3 months. She had been apparently healthy until 3 months ago, when she suddenly developed swelling in her right arm. The patient had no history of trauma, prolonged immobilization, strenuous exercise, or recent travel. She also denied experiencing chest pain, dyspnoea, headache, fever, palpitations, hemoptysis, or swelling of the feet. Initially, she was diagnosed with an inflammatory disease elsewhere and was prescribed anti-inflammatory drugs (NSAIDs), which temporarily reduced the swelling and pain, but the symptoms reappeared after a week. The patient had no comorbidities such as diabetes, hypertension, epilepsy, tuberculosis, or congestive heart disease. She also had no prior history of hospitalizations

or surgeries. On physical examination, non-pitting edema was observed in the right arm, with the mid-arm circumference of the right arm being 2 cm more than the left. Radial pulses were normal. Venous Doppler performed on 9th February 2024 showed a non-compressible, dilated right subclavian vein and axillary vein with an echogenic thrombus (Figure 1). Nerve conduction studies were performed on 9th February 2024 to rule out thoracic outlet syndrome, which was normal. The chest X-ray taken on 10th February 2024 revealed no bony deformities or mass lesions, and there was no evidence of central vein insertion. Computer Tomography (CT) venography, which was performed on 11th February 2024, confirmed a long segment intraluminal hypodense, non-enhancing filling defect in the right subclavian vein from its origin, extending into the axillary vein and brachial vein up to the upper third of the arm (Figure 2). A hypercoagulability workup was performed on 19th April 2024 (protein C, protein S, antiphos-

pholipid antibodies, homocysteine, lipoproteins, AT-III) was negative. With no underlying prothrombotic state or secondary causes identified, the DVT was attributed to primary causes, possibly idiopathic or Paget-Schroetter Syndrome (PSS), due to repeated use of the right upper limb and carrying a 5 kg weight over the right shoulder every day.

The patient was started on anticoagulant therapy, rivaroxaban 20 mg, a Direct Oral Anticoagulant (DOAC), along with ecospirin 75 mg. Thrombolysis was not performed due to delayed presentation. A subsequent Doppler scan after a month (on 15th April 2024) of treatment showed partial recanalization of the thrombus in the right subclavian vein (Figure 3). After 3 months of anticoagulant therapy, a repeat Doppler scan on 5th July 2024, showed complete resolution of the DVT (Figure 4). She continued anticoagulation therapy for an additional three months and remained under regular follow-up without any symptoms.

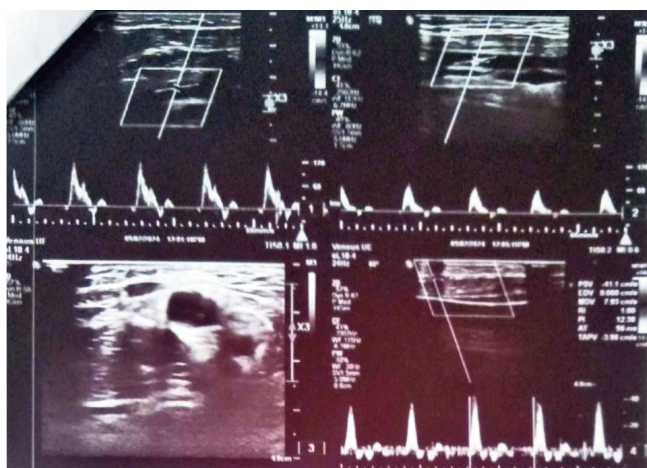


Figure 1. Venous Doppler study showing dilation of the right subclavian vein.

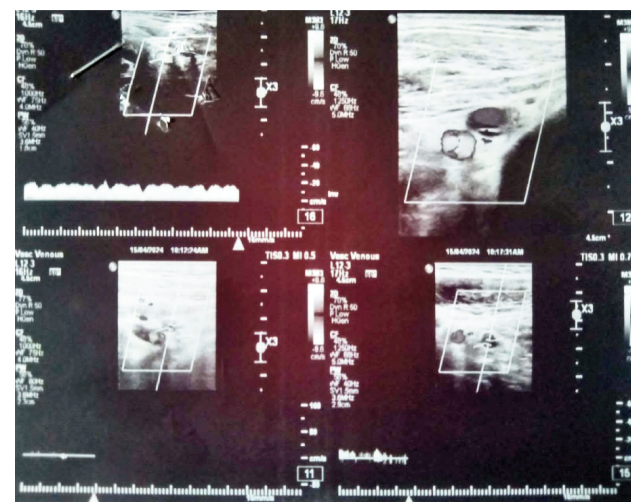


Figure 3. Venous Doppler study showing partial thrombosis after 1 month.

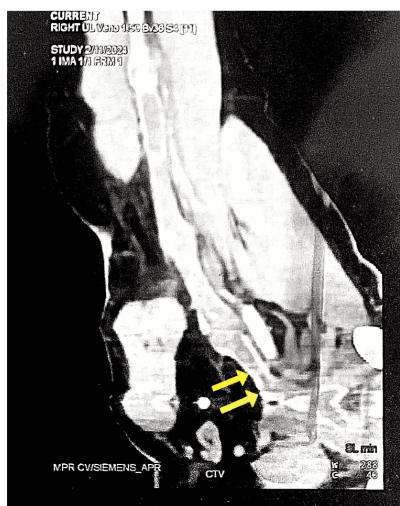

Figure 2. Computed Tomography (CT) venogram of right upper limb showing thrombus in subclavian and axillary vein.

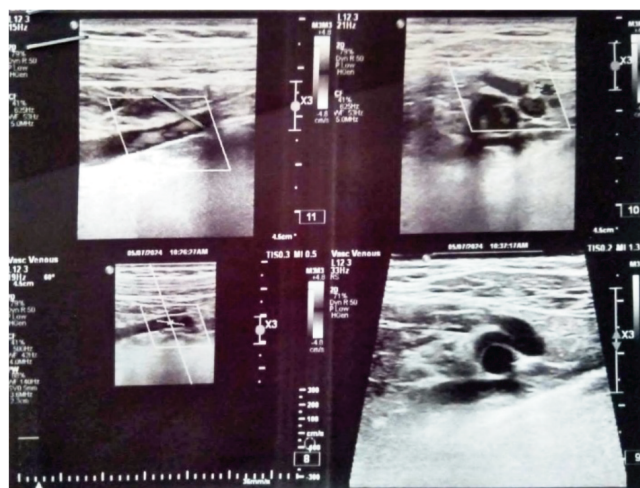


Figure 4. Venous Doppler study showing complete resolution after 3 months.

Discussion

DVT is an omnipresent clinical issue with critical worldwide mortality. Even though Lower extremity DVT is normal, UEDVT happens once in a long while. UEDVT was first perceived by the English pathologist and specialist Sir James Paget in 1855, consequently called PSS.⁵ Primary UEDVT, also known as Paget-Schroetter syndrome or effort thrombosis, is linked to repetitive or sudden physical exertion of the upper arm and obstruction of venous outflow caused by anatomical variations. UEDVT can lead to complications such as post-thrombotic syndrome (15%) and pulmonary embolism (15%), emphasizing the importance of early recognition and prompt initiation of anticoagulant therapy.⁶ Secondary UEDVT is commonly linked to malignancies or the use of intravenous devices, including central venous catheters and pacemaker leads.⁷

Pathophysiology

Thrombus formation in UEDVT is associated with Virchow's Triad: venous stasis, vascular injury, and hypercoagulability. The primary factor in the initiation and progression of thrombus is repeated microtrauma to the endothelium of the subclavian vein. In Paget-Schroetter Syndrome (PSS) and thoracic outlet obstruction, venous stasis is common, repetitive hyperabduction and extensive rotation can cause endothelial injury, activation of the coagulation cascade and perivenous fibrosis leading to thrombosis.⁸ Central

Venous Catheters (CVCs) contribute to both venous stasis and endothelial damage. Additionally, malignancies can create a hypercoagulable state and vascular injury, further increasing the thrombosis risk. There is no gender predisposition for UEDVT, as it occurs in both males and females. Patients presenting with UEDVT belong to the younger age group and are non-Caucasian when compared with LEDVT.⁹ This pattern was observed in our case study, which involves a young adult female in her early twenties.

Diagnosis

Compression duplex ultrasonography is the preferred diagnostic tool for upper extremity DVT, with a sensitivity of 97% due to its cost-effectiveness and widespread availability. The D-dimer test is useful for ruling out DVT in patients with low clinical suspicion.¹⁰ CT Venography is the gold standard test for confirming UEDVT. In some cases, where ultrasonography yields inconclusive results, CT venography is often done. Magnetic Resonance Imaging (MRI), can be a valuable alternative for diagnosing UEDVT. Coagulation studies should be done to rule out clotting disorders.¹¹

Treatment

The primary goal of treatment is to relieve symptoms caused by venous obstruction and to prevent complications such as recurrent Deep Vein Thrombosis (DVT). It is also essential to address any underlying secondary causes. Until about a decade ago, treat-

Table 1. The salient features of Upper Extremity Deep Vein Thrombosis (UEDVT).

Incidence	UEDVT constitutes up to 10% of DVT cases (0.4-1 per 10,000 persons per year)	
Types	Primary UEDVT: compression of axillary or subclavian vein due to anatomical variations Secondary UEDVT: associated with external factors like intravenous devices or malignancy	
Etiology	Primary UEDVT: Thoracic Outlet Syndrome (TOS) Repetitive strenuous exercise Anatomical variations Secondary UEDVT: Malignancy Use of intravenous devices Surgeries or trauma Blood clotting disorders Hormonal therapy Idiopathic causes.	
Symptoms	Pain, swelling, redness in the affected limb, non-pitting edema, larger mid-arm circumference, and normal radial pulses No chest pain, dyspnea, headache, fever, palpitations, hemoptysis, or swelling of the feet	
Investigations	Ultrasound (Doppler) CT venography Hypercoagulability profile that includes protein C, protein S, antiphospholipid antibodies, homocysteine, lipoproteins, ATIII Nerve Conduction Study (NCS) D-dimer test	
Treatment	Anticoagulant therapy: oral anticoagulants like DOACs are used at least for three months Thrombolysis or surgical decompression is considered for acute or severe cases Removal of catheter in patients having CVC-related thrombosis, followed by anticoagulation For anatomical abnormalities, Thoracic Outlet Decompression is done	
Complications	Post-thrombotic syndrome Pulmonary embolism (rare) Recurrent thromboembolism	
Conclusions	Early recognition and treatment of UEDVT is crucial for prevention of complications Diagnosis involve initial doppler study which is followed by CT venography or MRI if required Primarily anticoagulation therapy is given Early identification and treatment is essential, especially in young, active adults	

ment options were mainly limited to Low-Molecular-Weight Heparin (LMWH) or Vitamin K Antagonists (VKAs). However, recent advancements have introduced Direct Oral Anticoagulants (DOACs), including factor Xa inhibitors like apixaban and rivaroxaban, as well as thrombin inhibitors like dabigatran, which effectively prevent and treat DVT. The Swedish registry indicates that NOACs offer safe and effective treatment for upper extremity DVT.^{12,13} Thrombolysis is considered a potential treatment option for acute UEDVT affecting the axillary or more proximal veins if presented with in 14 days.¹³ Anticoagulation alone is effective in 29% while catheter directed thrombolysis was promising in nearly 80% of cases.^{14,15}

A treatment protocol involving thrombolysis followed by surgical decompression may be recommended for primary UEDVT cases presenting with acute and severe symptoms, unlike LEDVT. For patients with good surgical risk who are observed to have anatomical abnormalities associated with Thoracic Outlet Syndrome (TOS), Thoracic Outlet Decompression (TOD) should be performed.^{16,17} Removal of any underlying catheter is recommended for secondary DVT.¹⁸ Patients should receive at least three months of anticoagulation, with extended treatment recommended for those with active cancer or catheter-related UEDVT until the catheter is removed. While most patients see good outcomes, some may have persistent arm swelling due to subclavian vein conditions.¹⁷ Patients should be encouraged to adhere to all medication recommendations. Follow-up visits should be scheduled every 3 months in the first year and every 6 months for the next 2 years. Assessment for the signs of recurrence and consider venous Doppler ultrasounds every 6 to 12 months. Educating the patient on avoiding strenuous activities and recognition of symptoms of bleeding. Patients with hypercoagulable states should be made aware that they may need long-term anticoagulation.

In our case, the patient was started on oral anticoagulants due to a three-month history of symptoms. With a reduction in pain and swelling, thrombolysis was deferred.

The salient features of UEDVT are summarised in Table 1.

Conclusions

Primary UEDVT, or effort thrombosis, is suspected primarily in younger adults who were engaged in repetitive arm movements and presented with symptoms like pain and swelling of the upper limb. A Doppler study or CT venography will clinch the diagnosis. Early identification and immediate treatment are crucial in order to prevent the complications and morbidity associated with the disease.

References

- Singh O, Juneja D. Upper extremity deep vein thrombosis: an intensivist's perspective. *World J Crit Care Med* 2023;12:130-8.
- Constans J, Salmi LR, Sevestre-Pietri MA, et al. A clinical prediction score for upper extremity deep venous thrombosis. *Thromb Haemost* 2008;99:202-7.
- Erdem F, Keyik B, Çağlar B, et al. A rare cause of upper extremity deep venous thrombosis: Paget Schroetter syndrome. *J Surg Med* 2021;5:1230-2.
- Saleem T, Baril DT. Paget-Schroetter Syndrome. 2023. Available from: <https://www.ncbi.nlm.nih.gov/books/NBK482416/>
- Paget J. *Clinical lectures and essays*. Longmans, Green, and Company; London, UK; 1875.
- Sancho-González I, Bonilla-Hernández MV, Ibañez-Muñoz D, et al. Upper extremity deep vein thrombosis in a triathlete: again intense endurance exercise as a thrombogenic risk. *Am J Emerg Med* 2017;35:808.e1-3.
- Alqahtani FS, AlGhamdi A, Bawazeer AO, et al. Unraveling effort thrombosis: a comprehensive case report on Paget-Schroetter syndrome. *IJMDC* 2024;8:947-50.
- Amankwah KA, Agyemang S, Konadu E, et al. A rare occurrence of left radial vein thrombosis in a 23-year-old Ghanaian male—a case report. *Journal of Science and Technology (Ghana)* 2024;42:266741.
- De Farias LPG, Menezes DC, Faé IS, et al. Anatomical variations and congenital anomalies of the ribs revisited by multidetector computed tomography. *Radiol Bras* 2020;53:413-8.
- Hangge P, Rotellini-Coltvet L, Deipolyi AR, et al. Paget-Schroetter syndrome: treatment of venous thrombosis and outcomes. *Cardiovasc Diagn Ther* 2017;7:S285-90.
- Cho ES, McClelland PH, Cheng O, et al. Utility of d-dimer for diagnosis of deep vein thrombosis in coronavirus disease-19 infection. *Journal of Vascular Surgery: Venous and Lymphatic Disorders* 2021;9:47-53.
- Fuller T, Neville E, Shapiro J, et al. Comparison of aspiration thrombectomy to other endovascular therapies for proximal upper extremity deep venous thrombosis. *J Vasc Surg Venous Lymphat Disord* 2022;10:300-5.
- Palareti G. The recent clinical trials on use of the novel direct oral anticoagulants in patients with venous thromboembolism: a review. *Veins and Lymphatics* 2014;3:4148.
- Montiel FS, Ghazvinian R, Gottsäter A, Elf J. Treatment with direct oral anticoagulants in patients with upper extremity deep vein thrombosis. *Thromb J* 2017;15:26.
- Urschel HC, Razzuk MA. Paget-Schroetter syndrome: what is the best management? *Ann Thorac Surg* 2000;69:1663-8.
- Doyle A, Wolford HY, Davies MG, et al. Management of effort thrombosis of the subclavian vein: today's treatment. *Ann Vasc Surg* 2007;21:723-9.
- Pagani A, Baldazzi G, Ricci R, et al. An unusual case of venous thoracic outlet syndrome in relation to the anatomical position of the subclavian vein valves in a young athlete. *Veins and Lymphatics* 2023;12:11673.
- Scerrati A, Menegatti E, Zamboni M, et al. Internal jugular vein thrombosis: etiology, symptomatology, diagnosis and current treatment. *Diagnostics (Basel)* 2021;11:378.
- Bosch FTM, Nisio MD, Büller HR, van Es N. Diagnostic and therapeutic management of upper extremity deep vein thrombosis. *J Clin Med* 2020;9:2069.
- Duijzer D, de Winter MA, Nijkeuter M, et al. upper extremity deep vein thrombosis and asymptomatic vein occlusion in patients with transvenous leads: a systematic review and meta-analysis. *Front Cardiovasc Med* 2021;8:698336.

Received: 9 October 2024; Accepted: 12 December 2025; Early view: 13 March 2025.

Contributions: all the authors made a substantive intellectual contribution. All the authors have read and approved the final version of the manuscript and agreed to be held accountable for all aspects of the work.

Conflict of interest: the authors declare no potential conflict of interest.

Funding: none.

Ethics approval and consent to participate: not applicable.

Informed consent: not applicable.

Patient's consent for publication: the patient gave her written consent to use her personal data for the publication of this case report and any accompanying images.

Availability of data and materials: all data generated or analyzed during this study are included in this published article.

Publisher's note: all claims expressed in this article are solely those of the authors and do not necessarily represent those of their affiliated organizations, or those of the publisher, the editors and the reviewers. Any product that may be evaluated in this article or claim that may be made by its manufacturer is not guaranteed or endorsed by the publisher.

This work is licensed under a Creative Commons Attribution-NonCommercial 4.0 International License (CC BY-NC 4.0).