



eISSN 2279-7483

<https://www.pagepressjournals.org/index.php/vl/index>

**Publisher's disclaimer.** E-publishing ahead of print is increasingly important for the rapid dissemination of science. The **Early Access** service lets users access peer-reviewed articles well before print / regular issue publication, significantly reducing the time it takes for critical findings to reach the research community. These articles are searchable and citable by their DOI (Digital Object Identifier).

**Veins and Lymphatics** is, therefore, e-publishing PDF files of an early version of manuscripts that have undergone a regular peer review and have been accepted for publication, but have not been through the typesetting, pagination and proofreading processes, which may lead to differences between this version and the final one. The final version of the manuscript will then appear in a regular issue of the journal.

E-publishing of this PDF file has been approved by the authors.

*All legal disclaimers applicable to the journal apply to this production process as well.*

Veins and Lymphatics 2024 [online ahead of print]

To cite this article:

Paolo Eusebi, Ilaria Massi, Francesca Alesiani, Mirko Tessari. The association between the “T” vein and ulceration of the lateral aspect of the leg. *Veins and Lymphatics*. 2024;13:12882. doi:10.4081/vl.2024.12882

 ©The Author(s), 2024  
Licensee PAGEPress, Italy

*The publisher is not responsible for the content or functionality of any supporting information supplied by the authors. Any queries should be directed to the corresponding author for the article.  
All claims expressed in this article are solely those of the authors and do not necessarily represent those of their affiliated organizations, or those of the publisher, the editors and the reviewers.  
Any product that may be evaluated in this article or claim that may be made by its manufacturer is not guaranteed or endorsed by the publisher.*

## The association between the “T” vein and ulceration of the lateral aspect of the leg

Paolo Eusebi,<sup>1,2</sup> Ilaria Massi,<sup>1,2</sup> Francesca Alesiani,<sup>1,2</sup> Mirko Tessari<sup>1,2</sup>

<sup>1</sup>Department of Translational Medicine, School of Vascular Surgery, University of Ferrara;

<sup>2</sup>Program of Vascular Disease, University Hospital of Ferrara, Italy;

**Corresponding author:** Paolo Eusebi, School of Vascular Surgery, University of Ferrara, via Aldo Moro 8, 44124 Cona (FE), Italy.

Tel. +39 0532 239498. Fax. +39 0532 237443.

E-mail: [paolo.eusebi@edu.unife.it](mailto:paolo.eusebi@edu.unife.it)

**Key words:** tributary, reflux, leg ulcers, CHIVA, ligation.

**Authors' contributions:** PE, design, data acquisition, analysis and interpretation, drafting, revision; IM, design, data acquisition, analysis, and interpretation; FA, design, data acquisition; MT, design, analysis and interpretation, drafting, revision. All the authors have read and approved the final version of the manuscript and agreed to be held accountable for all aspects of the work.

**Conflict of interest:** the authors declare no potential conflict of interest.

*The publisher is not responsible for the content or functionality of any supporting information supplied by the authors. Any queries should be directed to the corresponding author for the article.  
All claims expressed in this article are solely those of the authors and do not necessarily represent those of their affiliated organizations, or those of the publisher, the editors and the reviewers.  
Any product that may be evaluated in this article or claim that may be made by its manufacturer is not guaranteed or endorsed by the publisher.*

**Funding:** none.

**Availability of data and materials:** all data generated or analyzed during this study are included in this published article.

**Ethics approval and consent to participate:** all procedures performed in the study were in accordance with the ethical standards of the Institutional Research Committee and with the 1964 Helsinki Declaration and its latest amendment.

**Informed consent:** all patients signed an informed consent form.

*The publisher is not responsible for the content or functionality of any supporting information supplied by the authors. Any queries should be directed to the corresponding author for the article.  
All claims expressed in this article are solely those of the authors and do not necessarily represent those of their affiliated organizations, or those of the publisher, the editors and the reviewers.  
Any product that may be evaluated in this article or claim that may be made by its manufacturer is not guaranteed or endorsed by the publisher.*

## Abstract

The “T” vein is a tributary of The Great Saphenous Vein (GSV) located in the upper third of the leg with a perpendicular course to the GSV. It usually crosses the tibial bone and feeds by reflux of varicose veins of the lateral aspect of the leg. It is of surgical interest because it is involved with a significant percentage of varicose networks.

The aim of this study is to analyze the prevalence of the T vein pattern in a cohort of patients affected by Chronic Venous Insufficiency (CVI), as well as its possible association with Venous Leg Ulcers (VLU) of the lateral aspect of the leg.

One thousand nine hundred and twenty-two consecutive patients (1441 females and 481 males) were evaluated from January 2013 to May 2024 by means of clinical examination and the same Duplex Ultrasound Scanning (DUS) protocol. We assessed the frequency of patients presenting with the T vein pattern and the percentage of patients in which it causes symptomatic reflux. We also evaluated the susceptibility, respectively in the T vein and in the CVI cohort, of venous ulcerations (C5-C6 clinical classes according to the Clinical, Etiological, Anatomical, and Pathophysiological, CEAP, classification) in the medial and/or in the medial and lateral aspect of the leg *vs* exclusively in the lateral aspect of the leg. A p-value <0.05 has been considered significant.

Overall, the presence of the T vein pattern was observed in 64 patients (3.33%). There is no statistically significant difference in the prevalence of T vein configuration in males (4.16%) and in females (3.05%) (p-value=0.24). A bilateral T vein pattern has been detected in just one case. T vein was involved in varicose vein networks, with only 2 patients being asymptomatic and without signs of CVI (3.1%). Noteworthy VLU (C5-C6) affected respectively 10 patients

*The publisher is not responsible for the content or functionality of any supporting information supplied by the authors. Any queries should be directed to the corresponding author for the article.*

*All claims expressed in this article are solely those of the authors and do not necessarily represent those of their affiliated organizations, or those of the publisher, the editors and the reviewers.*

*Any product that may be evaluated in this article or claim that may be made by its manufacturer is not guaranteed or endorsed by the publisher.*

of the T vein cohort and 74 of the control population; in the T vein cohort, 80% of patients presented with VLU in the lateral perimalleolar region, while 72.9% of patients in the control group had VLU in the typical medial perimalleolar area (p-value=0.000852).

Sometimes the clinician is doubtful about the venous pathogenesis of ulcerations visible in the lateral area of the leg. Our study suggests in these cases to investigate by DUS an eventual reflux coming from the T vein.

## Introduction

The venous system is composed of: Network N1, represented by all the venous structures located in the anatomical compartment below the deep fascia, such as the femoral veins, the popliteal vein, peroneal veins, gastrocnemius veins, and soleal veins - the rigid structures surrounding these veins, such as the deep fascia, muscular compartmental septa, bone planes, and the interosseous membrane, provide a certain degree of containment; Network N2, represented by the veins located in the saphenous compartment, between the deep and the superficial fascia - this compartment includes the Great Saphenous Vein (GSV), the small saphenous vein, the Anterior Accessory Saphenous Vein (AASV), and the Giacomini vein<sup>1</sup> - the duplication of the superficial fascia is responsible for the role of containment of the venous structures of this compartment, making it rare to find varicose saphenous veins;<sup>2-4</sup> and Network N3-N4, represented by the saphenous collaterals and intersaphenous branches running in subcutaneous compartment above the superficial fascia - since these veins are surrounded not by fascia but by adipose tissue, they lack containment systems - this is the reason why varicosity occurs mainly in these veins.

In addition, another relevant network is the perforating venous system,<sup>1,5</sup> which serves as a connection between N1 and N2 compartments. As for the N3 and N4 compartments, the veins of this system also do not present containment elements.<sup>6</sup>

The GSV belongs to the N2 network flowing in the saphenous compartment and it can be easily recognized in ultrasound transversal duplex imaging because of its characteristic Egyptian eye shape. The Egyptian eye is formed by a black pupil which is the anechogenic inner space of the GSV surrounded by the hyperechogenic superficial and deep layers of the fascia.<sup>1-4</sup>

*The publisher is not responsible for the content or functionality of any supporting information supplied by the authors. Any queries should be directed to the corresponding author for the article.*

*All claims expressed in this article are solely those of the authors and do not necessarily represent those of their affiliated organizations, or those of the publisher, the editors and the reviewers.*

*Any product that may be evaluated in this article or claim that may be made by its manufacturer is not guaranteed or endorsed by the publisher.*

In 2004 Zamboni *et al.* described for the first time an anatomic variant characterized by the presence of a tributary of the GSV located in the interfascial compartment, in the upper third of the leg. It runs transversely from the medial to the lateral part of the leg, crossing the tibia (Figure 1, Figure 2). Because of its perpendicular course to the GSV, it was named the “T” vein. T vein has a significant surgical interest because it is frequently involved in varicose networks since it transfers reflux from the GSV to the anterolateral surface of the leg leading to varicose veins in the lateral paratibial region.<sup>7</sup>

The aim of this study is to analyze a cohort of patients who present T vein patterns in order to investigate epidemiological data such as the prevalence in the Chronic Venous Insufficiency (CVI) population, as well as the respective prevalence in the female and the male sex. We also evaluated its possible association with Venous Leg Ulcers (VLU) of the lateral aspect of the leg. Finally, we aim to describe the surgical technique for treating T vein reflux by sparing the GSV, according to the principles of hemodynamic correction (CHIVA).

## Materials and Methods

One thousand nine hundred and twenty-two patients suffering from CVI of the lower limbs were investigated by means of Duplex Ultrasound Scanning (DUS) from January 2013 to May 2024.

DUS was performed in standing posture and the venous flow was elicited by squeezing and/or Wunstorf maneuver, in order to investigate the morphology and the hemodynamic pattern of the venous system of each patient; then a map was drawn by using a model (Figure 3)

*The publisher is not responsible for the content or functionality of any supporting information supplied by the authors. Any queries should be directed to the corresponding author for the article.  
All claims expressed in this article are solely those of the authors and do not necessarily represent those of their affiliated organizations, or those of the publisher, the editors and the reviewers.  
Any product that may be evaluated in this article or claim that may be made by its manufacturer is not guaranteed or endorsed by the publisher.*

The pre-operative map was created for each patient by entering the date of the patient's visit, name and surname and the clinical class in which the patient is classified at the time of the visit, according to the Clinical, Etiological, Anatomical, and Pathophysiological (CEAP) classification. Additionally, any risk factors in the patient's medical history were evaluated (advanced age, female gender, pregnancies, family history, sedentary lifestyle, overweight, and smoking habit). Following the evaluation through DUS of the venous flow in the lower limbs of the investigated patient, the hemodynamic patterns were reported on the map. This one schematizes the venous system representing the deep venous system as a single black arrow directed towards the heart and the superficial venous system with the GSV, small saphenous vein, and Giacomini vein. For each patient, the possible competence of The Sapheno-Femoral Junction (SFJ) was marked (in the example in the image it appears to be incompetent) and the direction of the venous flow in multiple segments of the GSV and the small saphenous vein was also evaluated (in the example in the image the small saphenous vein appears to be competent throughout its course, while the GSV appears to be incompetent up to the re-entry perforator). Additionally, the possible re-entry through a re-entry perforator (in blue in the image) and any varicosities (in red in the image) were marked; the example in the image specifically refers to varicose branches supplied by the refluxing T vein. Finally, the appropriate type of intervention for the investigated patient was reported in the "Notes" section. All patients signed an informed consent.

### ***Statistical analysis***

*The publisher is not responsible for the content or functionality of any supporting information supplied by the authors. Any queries should be directed to the corresponding author for the article.  
All claims expressed in this article are solely those of the authors and do not necessarily represent those of their affiliated organizations, or those of the publisher, the editors and the reviewers.  
Any product that may be evaluated in this article or claim that may be made by its manufacturer is not guaranteed or endorsed by the publisher.*



The prevalence of the T vein in patients affected by CVI, and respectively in males and females has been calculated by means of the Chi-squared test. By the means of Chi-squared test, we also calculated the susceptibility, respectively in the T vein and in the CVI cohort, of venous ulcerations (C5-C6) in the medial and/or in the medial and lateral aspect of the leg vs exclusively in the lateral aspect of the leg. A p-value <0.05 has been considered significant.

## Results

Overall, 1922 patients suffering from CVI of the lower limbs were investigated by means of DUS from January 2013 to May 2024. Among these, the T vein configuration was found in 64 patients, with a prevalence of 3.33%. In our cohort, we observed 44 female patients with T vein configuration out of a total of 1441 (3.05%) and 20 male patients with T vein configuration out of a total of 481 (4.16%) (Table 1). The average age of patients with T vein configuration was 55, the youngest was 23 years old, while the oldest was 78 years old. To evaluate the sex-related differences in the prevalence of the T vein configuration we performed a univariate analysis using odds ratio and we didn't obtain statistically significant differences (p-value=0.24).

Usually, this anatomical variant is not bilateral, in fact only one patient had this configuration in both legs. In most cases, we detected reflux in the T vein which determines a varicose network, and superficial varicose veins in the anterolateral part of the leg. Two patients did not complain of any symptoms, so we could assume that in this study T vein is asymptomatic in 3.1% of cases (Table 1).

Almost the totality of patients investigated in this study reported symptoms of CVI as C2, C3, and C4 classes of the CEAP classification: particularly 16 (25%) patients were classified as C2, 28 (43.75%) patients as C3, 10 (15.63%) patients as C4, 6 (9.37%) patients as C5, and 4 (6.25%) patients as C6 (Table 2).

Noteworthy VLU (C5-C6) affected respectively 10 patients (n=10/64; 15.6%) of the T vein cohort and 74 patients of the control population (n=74/(1992-64); 3.8%); in the T vein cohort, 80% of patients presented with VLU in the lateral perimalleolar region, while 72.9% of patients in the control group had VLU in the typical medial perimalleolar area (p-value=0.000852) (Table 3). In the present study, we did not find any difference in composition and clinical presentation of the classical VLU compared to that of the VLU from T vein reflux.

## Discussion

The T vein of the leg is a particular tributary of the GSV described for the first time in 2004.<sup>7</sup> The peculiarity of the T vein is the interfascial course, between the superficial and the deep fascia, instead of the suprafascial route of the other superficial tributaries of the GSV. The second characteristic of the T vein of the leg is its typical transversal direction from the medial aspect of the leg to the anterolateral one for at least 5 cm, crossing the anterior border of the tibia. Thirdly, the importance of the T vein is related to the hemodynamic patterns. In fact, the T vein is often involved in varicose clusters of the lateral aspect of the leg, with the re-entry perforators located distally in the same area. In our updated database only 3.1% of cases were asymptomatic. The vast majority of patients investigated in this study reported signs and symptoms of CVI: in particular 6 (9.37%) patients were classified as C5, and 4 (6.25%) patients

*The publisher is not responsible for the content or functionality of any supporting information supplied by the authors. Any queries should be directed to the corresponding author for the article.*

*All claims expressed in this article are solely those of the authors and do not necessarily represent those of their affiliated organizations, or those of the publisher, the editors and the reviewers.*

*Any product that may be evaluated in this article or claim that may be made by its manufacturer is not guaranteed or endorsed by the publisher.*

as C6 (Table 2). Intriguingly, as hinted before, among the 10 patients with active and/or healed ulceration (C5-C6), 8 (80%) presented with the vascular lesion exclusively in the lateral perimalleolar region (Table 3). This observation suggests that the T vein reflux flow, crossing from the medial to the lateral aspect of the leg, determines an overload of venous hypertension which favors the appearance of VLU in the lateral malleolar or perimalleolar region. This is quite unusual because it is well known that the majority of VLU develop in the medial perimalleolar region. This is also confirmed in our CVI cohort of C5-C6 patients where 72.9% of patients showed VLU in the medial and/or medial and lateral aspect of the leg. Such a different behavior explains the strong statistical differences we found regarding the area of VLU appearance.

There are no differences in the presentation of VLU between the classic ones and those related to reflux from the T vein. In the present study, we did not detect differences in the composition of the ulcer, in its shape, edges, and dimensions; the venous ulcerative lesions resulting from reflux from the T vein have a clinical presentation similar to the classic ones, with the following characteristics: variable ulcer dimensions and irregular edges, possible formation of fibrinous zones within the ulcer, possible association with pain that increases with standing in an upright position, edema of the affected limb, white atrophy with loss of skin pigmentation at the edge of the lesion caused by the death of red blood cells and scarring, association with superficial varicose veins, lipodermatosclerosis - a hardening of the skin that gives the appearance of an "inverted champagne bottle".

The main difference between classic VLU and those from T vein reflux is that the former present themselves in the vast majority of cases in the medial perimalleolar area, while in most

cases ulcers resulting from T vein reflux are localized in the lateral perimalleolar area; in particular, in the present study, 80% of patients with T vein reflux present VLU in the lateral malleolar level. This type of ulcer must not be confused with the Arteriolosclerotic Ulcer of Martorell (ASUM),<sup>8,9</sup> as the latter also is usually located at the anterolateral aspect of the leg and in the lateral perimalleolar area. It is an arterial ulcer whose main etiopathological cause is represented by arterial hypertension and the consequent effects it determines at the arteriolar level. Chronic uncontrolled arterial hypertension typically leads to the formation of nummular papules at the anterior or medial aspect of the leg; subsequently, a painful red blister forms, sometimes due to local trauma, which then becomes purplish and ulcerates; the ulcer appears necrotic inside, in most cases being superficial and with red-purple edges. The accentuated pain is characteristic, usually greater than that of VLU from the T vein, often leading to insomnia. ASUM mainly affects female patients between 50 and 70 years old with arterial hypertension<sup>9</sup>. The differential diagnosis between the two types of ulcers must be based initially on the clinical presentation of the ulcer and the surrounding skin: VLU from the T vein is not dissimilar to a classic VLU and presents with variable dimensions and irregular edges, often with white atrophy, fibrinous zones at the base of the ulcer, and possible association with pain, usually more moderate than that typical of ASUM, increasing with the maintenance of a static upright position; it can also be associated with lipodermatosclerosis, edema and varicose veins in the surrounding areas. Instead, ASUM, since it is an arterial ulcer, clinically presents most of the time as a superficial ulcer, with central necrosis and purplish or reddish edges of the ulcer, usually without limb edema and varicose veins, fibrinous zones within the ulcer, and perilesional white atrophy. The association with pain increases in the supine position as further

*The publisher is not responsible for the content or functionality of any supporting information supplied by the authors. Any queries should be directed to the corresponding author for the article.*

*All claims expressed in this article are solely those of the authors and do not necessarily represent those of their affiliated organizations, or those of the publisher, the editors and the reviewers.*

*Any product that may be evaluated in this article or claim that may be made by its manufacturer is not guaranteed or endorsed by the publisher.*

reduction of blood flow to the lower limbs occurs, while it improves in an upright position; this is another element that can help in the differential diagnosis of venous ulcers. Furthermore, a thorough patient history can help determine an arterial or venous etiology; the patient with ASUM typically has arterial hypertension, smoking habit, diabetes mellitus, and/or other cardiovascular risk factors, while the patient with VLU from T vein reflux presents the typical risk factors of CVI (advanced age, female gender, pregnancies, family history, sedentary lifestyle, overweight, and smoking habit); finally, a careful assessment with arterial and venous DUS allows for confirmation of the differential diagnosis.

Our data suggest that in the presence of varicose veins in the lateral aspect of the leg, it is mandatory to investigate whether there is a T vein as a source of venous reflux. The diagnosis of the presence of the T vein and the reflux pattern were obtained through the duplex ultrasound examination: a high-resolution B-mode investigation was useful to identify the T vein of the leg and its outlet from the GSV, dynamic tests in orthostatism were performed to define the reflux.

Since the outlet of the T vein is interfascial, whatever technique - hemodynamic correction (CHIVA),<sup>10-15</sup> Endovenous Laser Ablation (EVLA),<sup>16-18</sup> Radiofrequency Ablation (RFA),<sup>19</sup> Ultrasound-Guided Foam Sclerotherapy (UGFS) and Mechanico Chemical Ablation (MOCA) - for the surgical management of CVI the reader uses, it is necessary to open the superficial fascia in order to perform a flush ligation and division of the T vein so avoiding recurrences from a long stump in the follow-up; the long interfascial route of the T vein warrants a flush ligation and division of the origin of the vein from the GSV (Figure 4).

As significantly demonstrated by SAPTAP,<sup>20</sup> treatment with Simple Ambulatory Phlebectomy (SAP) in patients with CVI with incompetent great saphenous vein or AASV and one or more incompetent tributaries is not inferior to treatment with endothermal ablation of the GSV and/or AASV with concomitant phlebectomy (TAP). This results in avoiding an additional treatment of the saphenous trunk in 73.5% of cases, based on a one-year follow-up. This means that with simple SAP, the complete abolition of symptoms was achieved in 3/4 of patients with saphenofemoral reflux and peripheral varices.

Nevertheless, our data outline that in cases where there is a T vein as a source of reflux for distal varices, simple SAP leads to symptomatic recurrence in the majority of patients. In these cases simple ambulatory phlebectomy sec. Muller of the lateral aspect of the leg cannot be considered an effective treatment. Therapeutic success can only be achieved through a flush ligation and division of the T vein from the GSV; this procedure requests surgical precision that needs a 1.5-2 cm incision and a superficial fascia opening.

## Conclusions

Sometimes the clinician is doubtful about the venous pathogenesis of ulcerations visible in the lateral area of the leg. Our study demonstrated the intriguing relationship between VLU in the unusual position of the lateral perimalleolar region and the reflux coming from the T vein. Since the latter is interfascial its reflux can be demonstrated only by DUS, because the enlargement of this vein cannot be seen by the naked eye. We recommend investigating and treating it properly in case of ulceration of the lateral aspect of the leg.

## References

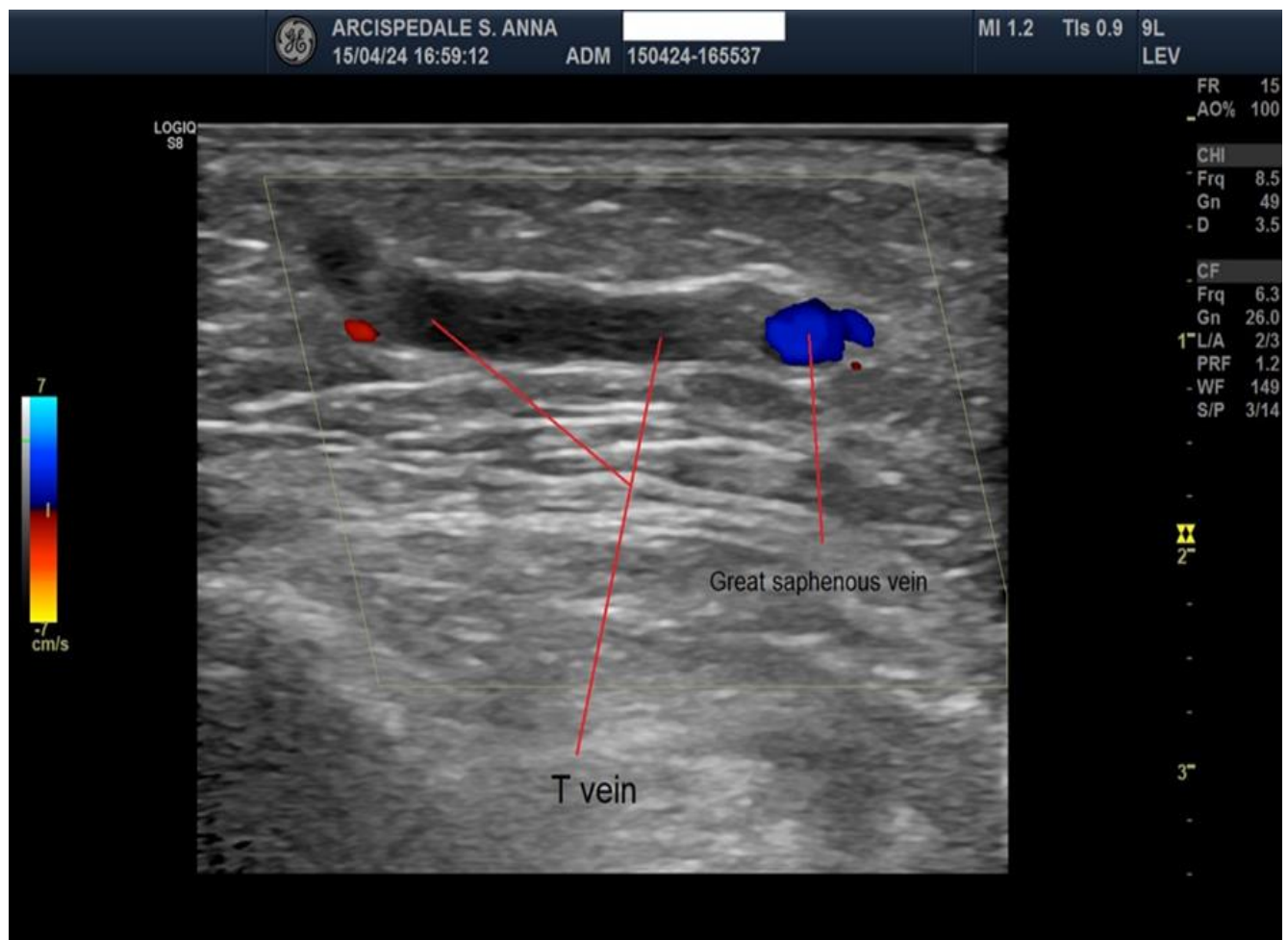
1. Cavezzi A, Labropoulos N, Partsch H, et al. Duplex ultrasound investigation of the veins in chronic venous disease of the lower limbs-UIP consensus document. *Eur J Vasc Endovasc Surg* 2006;31:288-99.
2. Zamboni P, Marcellino MG, Cappelli M, et al. Saphenous vein sparing surgery: principles, techniques and results. *J Cardiovasc Surg* 1998;39:151-62.
3. Zamboni P, Cappelli M, Marcellino MG, et al. Does a varicose saphenous vein exist? *Phlebology: the Journal of Venous Disease* 1997;12:74-7.
4. Mazayshvili K. The superficial venous pump. *Veins and Lymphatics* 2018;7:7280.
5. Caggiati A, Bergan JJ, Gloviczki P, et al. Nomenclature of the veins of the lower limbs: an international interdisciplinary consensus statement. *J Vasc Surg* 2002;36:416-22.
6. Zamboni P. *La chirurgia conservativa del sistema venoso superficiale*. First edition. Gruppo Editoriale Faenza Editrice; Faenza, Italy; 1996.
7. Zamboni P, De Palma M, Carandina S, et al. The “T” vein of the leg. *Dermatol Surg* 2004;30:750-2.
8. Vuerstaek JDD, Reeder SWI, Henquet CJM, Neumann HAM. Arteriolosclerotic ulcer of Martorell. *J Eur Acad Dermatol Venereol* 2010;24:867-74.
9. Pinto A, Silva N, Osorio C et al. Martorell’s ulcer: diagnostic and therapeutic challenge. *Case Rep Dermatol* 2015;7:199-206.
10. Chi Y-W. A new textbook for saphenous vein sparing surgery: CHIVA strategy permits to achieve the goal also using modern endovascular technology. *Veins and Lymphatics*. 2019;8:7936.

*The publisher is not responsible for the content or functionality of any supporting information supplied by the authors. Any queries should be directed to the corresponding author for the article.  
All claims expressed in this article are solely those of the authors and do not necessarily represent those of their affiliated organizations, or those of the publisher, the editors and the reviewers.  
Any product that may be evaluated in this article or claim that may be made by its manufacturer is not guaranteed or endorsed by the publisher.*

11. Franceschi C, Cappelli M, Ermini S, et al. CHIVA: hemodynamic concept, strategy and results. *International Angiology* 2016;35:8-30.
12. Cappelli M, Molino Lova R, Pinelli M, Franceschi C. The troubled course of the CHIVA cure through clinical studies: a critical review. *Veins and Lymphatics* 2023;12:11886.
13. Del Frate R, Bricchi M, Franceschi C, Goldoni M. Multiple ligation of the proximal greater saphenous vein in the CHIVA treatment of primary varicose veins. *Veins and Lymphatics* 2014;3:19-22.
14. Parés JO, Juan J, Tellez R, et al. Varicose vein surgery: stripping versus the CHIVA method: a randomized controlled trial. *Ann Surg* 2010;251:624-31.
15. Zamboni P, Cisno C, Marchetti F, et al. Minimally invasive surgical management of primary venous ulcers vs. compression treatment: a randomized clinical trial. *Eur J Vasc Endovasc Surg* 2003;25:313-8.
16. Darwood RJ, Gough MJ. Endovenous laser treatment for uncomplicated varicose veins. *Phlebology* 2009;24:50-61.
17. Zini F, Tessari R, Torre R. Sclerofoam assisted laser therapy for saphenous refluxes: an innovative tumescence-free technique. *Veins and Lymphatics* 2015;5:31-3.
18. Giancesini S, Menegatti E, Zuolo M, et al. Laser-assisted strategy for reflux abolition in a modified CHIVA approach. *Veins and Lymphatics* 2015;4:53-7.
19. Proebstle TM, Vago B, Alm J, et al. Treatment of the incompetent great saphenous vein by endovenous radiofrequency powered segmental thermal ablation: first clinical experience. *J Vasc Surg* 2008;47:151-6.

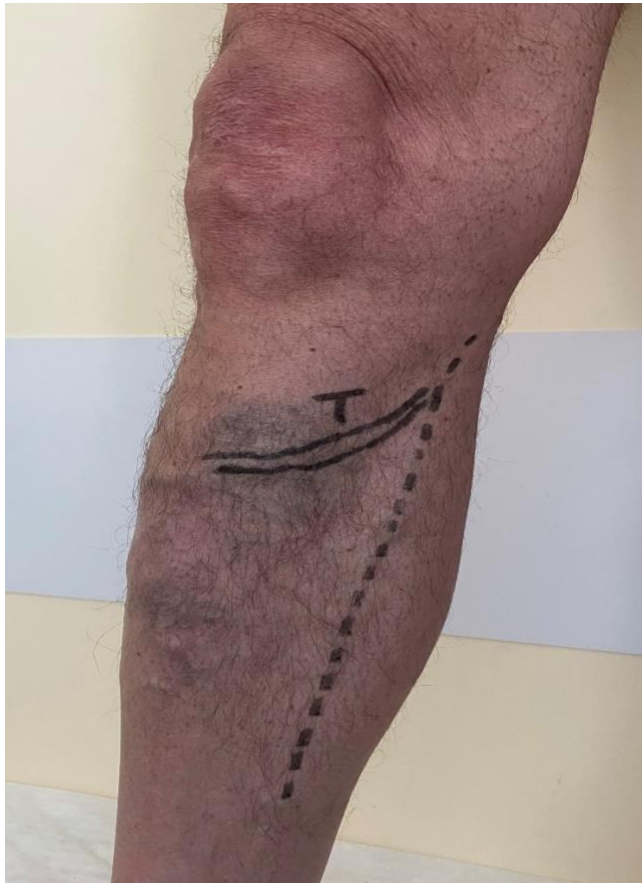

20. Scheerders E, Van der Velden S, Goossens L, et al. A randomized clinical trial of isolated ambulatory phlebectomy versus saphenous thermal ablation with concomitant phlebectomy (SAPTAP Trial). *Br J Surg* 2023;110:333-42.



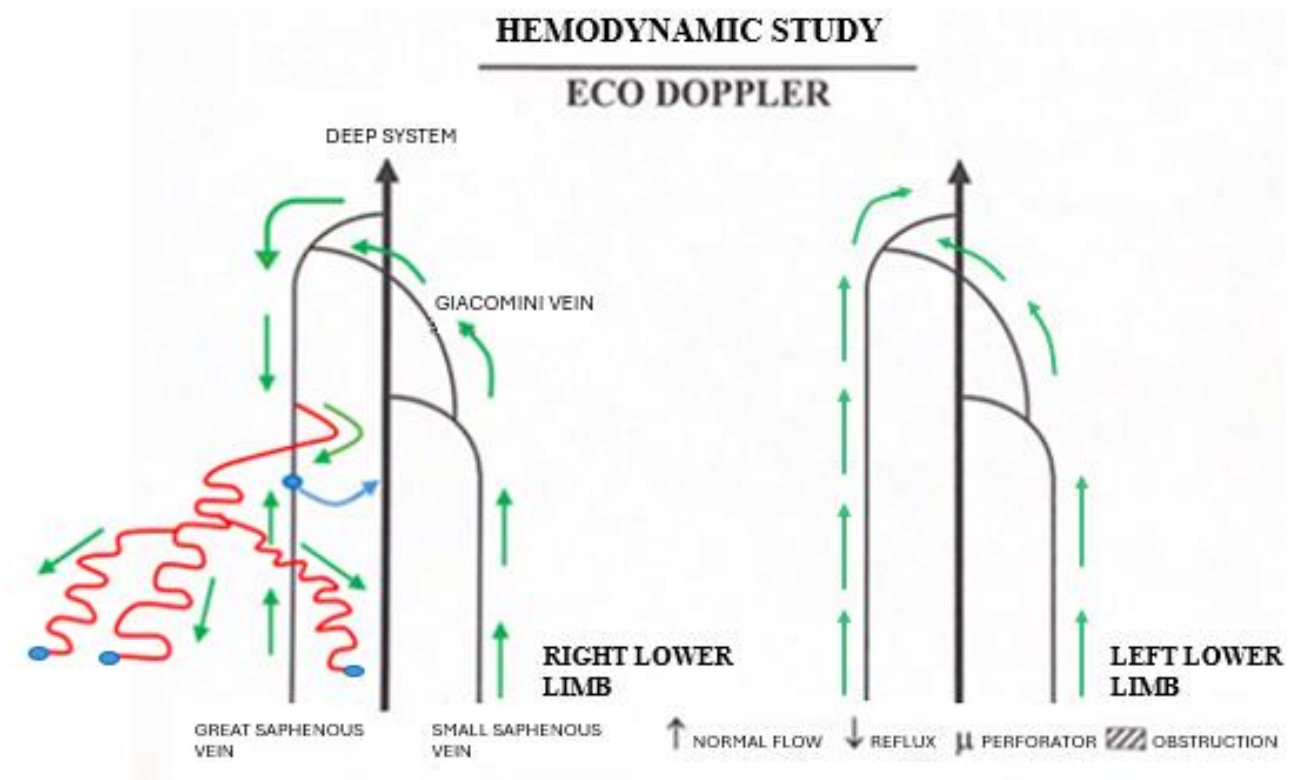
**Figure 1.** Ultrasound transversal duplex image documenting the origin of the T vein from the Great Saphenous Vein (GSV) and its perpendicular course towards the tibial region.

*The publisher is not responsible for the content or functionality of any supporting information supplied by the authors. Any queries should be directed to the corresponding author for the article.  
All claims expressed in this article are solely those of the authors and do not necessarily represent those of their affiliated organizations, or those of the publisher, the editors and the reviewers.  
Any product that may be evaluated in this article or claim that may be made by its manufacturer is not guaranteed or endorsed by the publisher.*



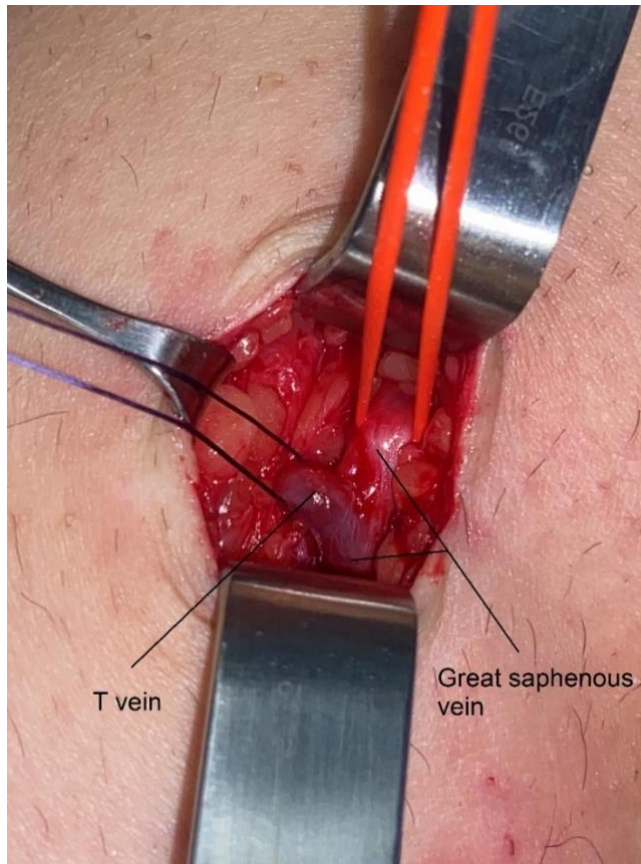
**Figure 2.** Anatomical position of the T vein and varices of the lateral aspect of the leg.

*The publisher is not responsible for the content or functionality of any supporting information supplied by the authors. Any queries should be directed to the corresponding author for the article.  
All claims expressed in this article are solely those of the authors and do not necessarily represent those of their affiliated organizations, or those of the publisher, the editors and the reviewers.  
Any product that may be evaluated in this article or claim that may be made by its manufacturer is not guaranteed or endorsed by the publisher.*



**Figure 3.** Pre-operative hemodynamic map model used in University Hospital of Ferrara, Italy. Blue dots, re-entry perforator; green arrows, direction of the venous flow; red segments, varicose veins of the N3 network in the lateral aspect of the leg fed by reflux of the T vein.

*The publisher is not responsible for the content or functionality of any supporting information supplied by the authors. Any queries should be directed to the corresponding author for the article. All claims expressed in this article are solely those of the authors and do not necessarily represent those of their affiliated organizations, or those of the publisher, the editors and the reviewers. Any product that may be evaluated in this article or claim that may be made by its manufacturer is not guaranteed or endorsed by the publisher.*



**Figure 4.** Anatomical aspect of the T vein origin from the Great Saphenous Vein (GSV) before the flush ligation.

*The publisher is not responsible for the content or functionality of any supporting information supplied by the authors. Any queries should be directed to the corresponding author for the article.  
All claims expressed in this article are solely those of the authors and do not necessarily represent those of their affiliated organizations, or those of the publisher, the editors and the reviewers.  
Any product that may be evaluated in this article or claim that may be made by its manufacturer is not guaranteed or endorsed by the publisher.*

**Table 1.** Main data about the T vein obtained in the study.

	<b>Total number</b>	<b>Percentage (%)</b>
<b>Cohort patients</b>	1922	
Female	1441	74.97
Male	481	25.03
<b>T vein</b>	64	3.33
Female	44	3.05
Male	20	4.16
<b>Bilateral T vein</b>	1	1.56
<b>Asymptomatic</b>	2	3.1

*The publisher is not responsible for the content or functionality of any supporting information supplied by the authors. Any queries should be directed to the corresponding author for the article.  
All claims expressed in this article are solely those of the authors and do not necessarily represent those of their affiliated organizations, or those of the publisher, the editors and the reviewers.  
Any product that may be evaluated in this article or claim that may be made by its manufacturer is not guaranteed or endorsed by the publisher.*

**Table 2.** Clinical, Etiological, Anatomical, and Pathophysiological (CEAP) classification of venous disorders of the lower limbs investigated in patients with the T vein in the conducted study.

CEAP classification	Total number	Percentage (%)
C0	0	0
C1	0	0
C2	16	25.00
C3	28	43.75
C4	10	15.63
C5	6	9.37
C6	4	6.25

*The publisher is not responsible for the content or functionality of any supporting information supplied by the authors. Any queries should be directed to the corresponding author for the article.  
All claims expressed in this article are solely those of the authors and do not necessarily represent those of their affiliated organizations, or those of the publisher, the editors and the reviewers.  
Any product that may be evaluated in this article or claim that may be made by its manufacturer is not guaranteed or endorsed by the publisher.*

**Table 3.** Main data about Venous Leg Ulcers (VLU) obtained in the conducted study.

	<b>T vein cohort</b>	<b>CVI cohort</b>
VLU	10 (15.6%)	74 (3.83%)
Medial and/or medial and lateral	2 (20%)	54 (72.9%)
Just lateral	8 (80%)	20 (27.1%)

CVI, Chronic Venous Insufficiency

*The publisher is not responsible for the content or functionality of any supporting information supplied by the authors. Any queries should be directed to the corresponding author for the article.  
All claims expressed in this article are solely those of the authors and do not necessarily represent those of their affiliated organizations, or those of the publisher, the editors and the reviewers.  
Any product that may be evaluated in this article or claim that may be made by its manufacturer is not guaranteed or endorsed by the publisher.*