

## Secondary organizing pneumonia complicating influenza B

Rahul Tyagi,<sup>1</sup> Utkarsh Suyal,<sup>1</sup> Kislay Kishore,<sup>1</sup> Monika Aggarwal,<sup>2</sup> Shrinath V.<sup>3</sup>

<sup>1</sup>Department of Respiratory Medicine, Army Institute of Cardiothoracic Sciences/Armed Forces Medical College, Pune; <sup>2</sup>Department of Pathology, Army Institute of Cardiothoracic Sciences/Armed Forces Medical College, Pune; <sup>3</sup>Department of Respiratory Medicine, INHS Asvini, Mumbai, India

### Abstract

Influenza A and B viruses cause acute viral respiratory illness and can cause various respiratory complications, including influenza pneumonia and coinfection with other bacteria. Secondary Organizing Pneumonia (SOP) has rarely been reported as a complication of influenza pneumonia. Most of these cases are secondary to influenza A. SOP due to influenza B is seldom reported. We report a patient with influenza B pneumonia with

persistent clinical and radiological worsening despite antivirals and antibiotics. A differential diagnosis of either secondary infection or SOP was considered. The patient underwent fiberoptic bronchoscopy and bronchoalveolar lavage, which ruled out infection. The patient was managed as SOP with steroids and had a good response to treatment. The use of steroids in influenza has been shown to worsen mortality. However, in our patient, once infection was ruled out, steroids proved to be lifesaving.

### Case Report

A 40-year-old overweight (Body Mass Index, BMI, 27.44 kg/m<sup>2</sup>) male, a former smoker with diabetes mellitus for the past six years, managed with oral hypoglycaemic agents presented to the emergency department with a 5-day history of fever, sore throat, and productive cough, along with three days of progressive dyspnoea and loose stools. Initial evaluation revealed fever (101°F), tachycardia (heart rate 102/min, and tachypnoea - respiratory rate 24/min) with a Saturation of Peripheral Oxygen (SpO<sub>2</sub>) of 94% on room air. Chest examination revealed bilateral basal crackles, with the rest of the systemic examination being unremarkable. Lab results showed Haemoglobin (Hb) of 15.6 g/dL, Total Lymphocyte Count (TLC) of 4200/mm<sup>3</sup>, N68% L22% M06% E04%, random blood glucose of 310 mg/dL, Glycated Haemoglobin (HbA1C) of 11.6%, and positive urinary ketones. The initial chest radiograph showed air space opacities in the left lower zone. He was managed with intravenous fluids, broad-spectrum antibiotics (ceftriaxone), and insulin to achieve adequate glycaemic control. Despite therapy, his condition deteriorated, leading to worsening respiratory failure (SpO<sub>2</sub> of 80% on room air, 96% on 8 L/min oxygen). Inflammatory markers were elevated (C-Reactive Protein, CRP, 56 mg/dL, D-dimer -5.17 mg/dL), and repeat chest radiograph showed bilateral, diffuse areas of non-homogenous opacities with predominantly peripheral distribution (Figure 1). High-Resolution Computed Tomography (HRCT) of the chest showed multiple sub-pleural consolidation areas with interlobular septal thickening affecting both lung fields with sub-pleural and basal distribution (Figure 2). His blood and sputum cultures were negative for any infective pathogens and procalcitonin levels were normal (<0.05 mg/dl). His nasopharyngeal swab was negative for COVID-19 and tested positive for influenza B via Reverse Transcriptase Polymerase Chain Reaction (RT-PCR). The patient was prescribed oseltamivir and broad-spectrum antibiotics (piperacillin-tazobactam and levofloxacin) to cover potential bacterial co-infections. Despite treatment, his condition worsened with increasing breathlessness and oxygen requirement. His chest radiograph also did not reveal any significant resolution. A follow-up HRCT chest showed diffuse, patchy consolidation with occasional ground glass opacities involving bilateral lung parenchyma, with areas of consolidation predominantly peripheral and sub-pleural and predominating basal and posteriorly with some areas of consolidation showing a central halo in some regions ("reverse

Correspondence: Rahul Tyagi, Department of Respiratory Medicine, Army Institute of Cardiothoracic Sciences/Armed Forces Medical College, Pune, India.

E-mail: rahultyagi4960@gmail.com

Key words: Secondary Organizing Pneumonia, atoll sign, influenza B.

Contributions: all the authors made a substantive intellectual contribution. All the authors have read and approved the final version of the manuscript and agreed to be held accountable for all aspects of the work.

Conflict of interest: the author declares no potential conflict of interest.

Funding: none.

Ethics approval and consent to participate: not applicable.

Patient's consent for publication: the patient gave his written consent to use his personal data for the publication of this case report and any accompanying images.

Availability of data and materials: all data generated or analyzed during this study are included in this published article.

Received: 15 July 2024.

Accepted: 21 August 2024.

Early view: 23 August 2024.

This work is licensed under a Creative Commons Attribution-NonCommercial 4.0 International License (CC BY-NC 4.0).

©Copyright: the Author(s), 2024

Licensee PAGEPress, Italy

Chest Disease Reports 2024; 12:12812

doi:10.4081/cdr.2024.12812

*Publisher's note: all claims expressed in this article are solely those of the authors and do not necessarily represent those of their affiliated organizations, or those of the publisher, the editors and the reviewers. Any product that may be evaluated in this article or claim that may be made by its manufacturer is not guaranteed or endorsed by the publisher.*

halo or atoll sign”) (Figure 3), indicating radiological progression.

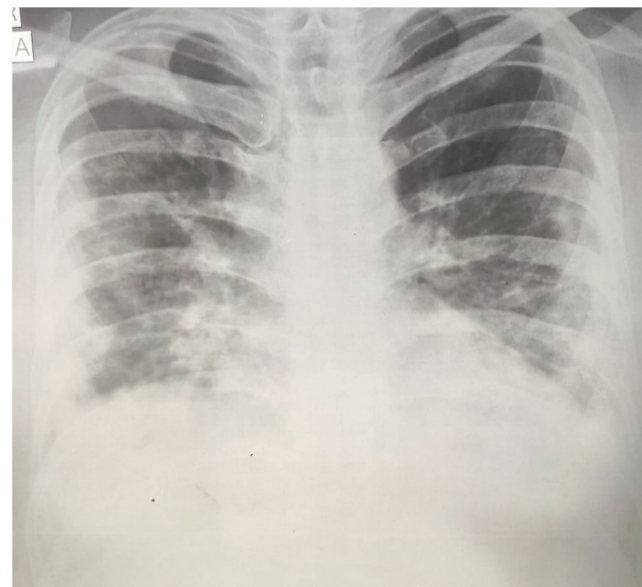
Given the patient’s worsening symptoms while on antiviral and antibiotics, HRCT showing progressive worsening with predominant peripheral opacities and poor glycaemic control, secondary bacterial/fungal infection was initially suspected. However, due to the presence of an “atoll sign” on HRCT, Secondary Organizing Pneumonia (SOP) was also considered a possibility.

The patient was planned for fiberoptic bronchoscopy with Broncho-Alveolar Lavage (BAL) and Trans-Bronchial Lung Biopsy (TBLB). He underwent fiberoptic bronchoscopy on oxygen support with a Fraction of Inspired Oxygen (FiO<sub>2</sub>) of 60%, post BAL he de-saturated and TBLB could not be carried out. His BAL was sent for multiplex PCR which was again positive for influenza B, and negative for all other bacteria and viruses studied, including COVID-19. Conventional pyogenic culture of BAL, Acid Fast Bacilli (AFB) stain, and Gene Xpert for *Mycobacterium tuberculosis*, all returned negative results. Similarly, BAL fungal stain, culture, and galactomannan tests were also negative. BAL cytology showed predominantly alveolar macrophages (90%), and only occasional polymorphs, no organisms/eosinophilia/atypia was seen. Serum procalcitonin was <0.05 mg/dL. A detailed clinical assessment that did not support an underlying autoimmune condition and his Anti-Nuclear Antibody (ANA), Extractable Nuclear Antigen (ENA) panel, and Anti-Cyclic Citrullinated Peptide (Anti CCP) were all negative. Based on the clinical picture, the HRCT chest showed an “atoll sign” and negative infection and autoimmune work-up, and he was diagnosed with SOP.

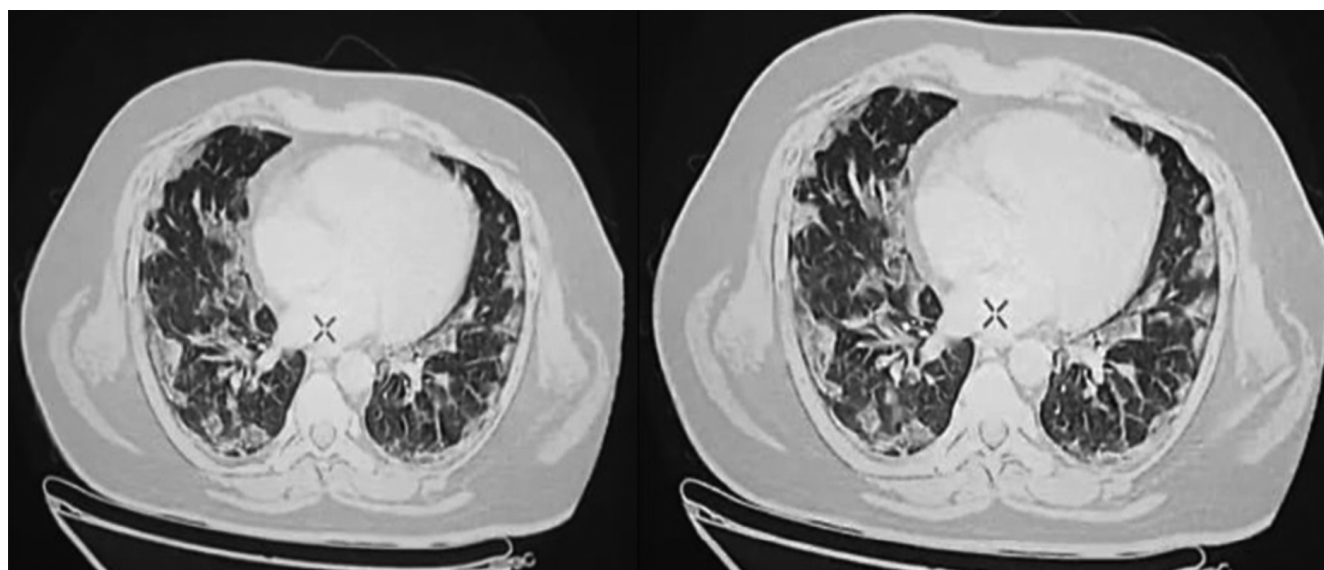
The patient was started on prednisolone 60 mg (1 mg/kg/day), insulin for glycaemic control, and antibiotics (piperacillin-tazobactam and levofloxacin) were continued till clinical and radiological improvement was confirmed. The patient’s dyspnoea and exercise tolerance improved markedly, with a chest radiograph showing significant resolution of opacities within seven days of starting prednisolone. Steroids were tapered over the next 6 weeks. He was discharged on room air and returned to work 4 weeks after discharge from the hospital. Repeat HRCT after 4 weeks of gradual tapering dose of prednisolone showed complete resolution of opacities (Figure 4).

## Discussion

Influenza A and B viruses are known to cause acute viral respiratory illness.<sup>1</sup> Influenza virus infection in adults can cause a variety of respiratory complications including influenza pneumonia and coinfection with other bacteria like *Streptococcus pneumoniae* and *Staphylococcus aureus*.<sup>1</sup> SOP has been only reported rarely as a complication of Influenza pneumonia.<sup>2-6</sup> Most of these cases are secondary to influenza A.<sup>3-5,7-9</sup> SOP due to influenza B is rarely reported.<sup>2,6,10</sup> Asai *et al.* reported the first case of SOP due to influenza B in 2017.<sup>2</sup> Clinical management of patients admitted with influenza includes management of complications like hypox-



**Figure 1.** Chest radiograph showed bilateral diffuse areas of non-homogenous opacities with predominantly peripheral distribution.



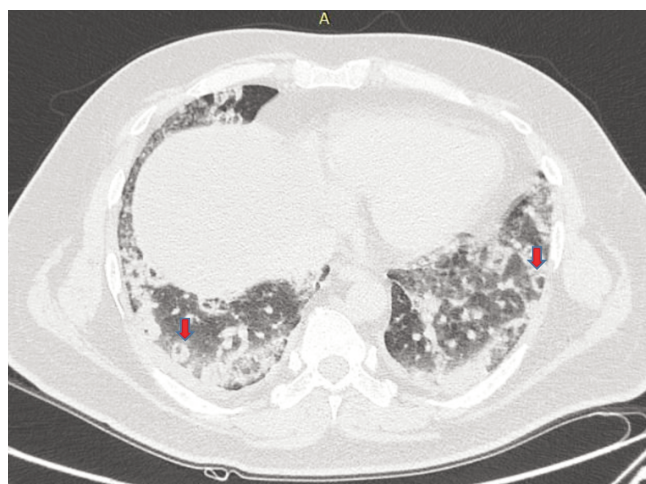
**Figure 2.** High-Resolution Computed Tomography (HRCT) of the chest shows multiple subpleural consolidation areas with interlobular septal thickening affecting both lung fields with subpleural and basal distribution.



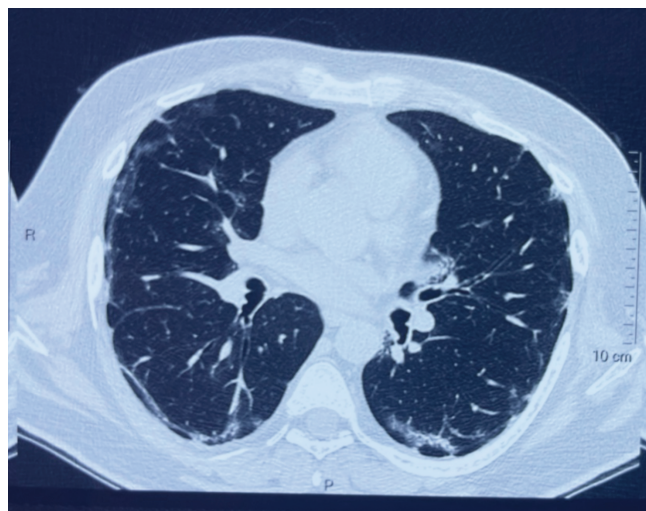
emia with supplemental oxygen, critical care support including non-invasive and invasive ventilation, antibiotics for bacterial confection and advanced organ support like Extracorporeal Membrane Oxygen (ECMO), haemodialysis and haemodynamic support as required.<sup>1</sup>

The use of steroids in influenza remains controversial.<sup>1</sup> Metanalysis of various observational studies<sup>11</sup> and one Randomized Controlled Trial (RCT) with various observational studies<sup>12</sup> has shown that corticosteroid treatment increases mortality in influenza pneumonia and Acute Respiratory Distress Syndrome (ARDS). Both meta-analyses reported that steroids increased the risk of hospital-acquired infections

Influenza B causing secondary organizing pneumonia was first



**Figure 3.** Repeat High-Resolution Computed Tomography (HRCT) of the chest showing diffuse, patchy consolidation with ground glass opacities involving bilateral lung parenchyma. Areas of consolidation that are predominantly peripheral and subpleural with basal and posterior predominance and some areas of consolidation showing a central halo (Red arrow) were seen.



**Figure 4.** Repeat High-Resolution Computed Tomography (HRCT) showing near complete resolution after 4 weeks of discharge.

reported by Asai *et al.*<sup>2</sup> in a 23-year-old female patient without any known comorbidities. Shah *et al.*<sup>10</sup> and Kwok *et al.*<sup>6</sup> have also reported cases of influenza B pneumonia causing SOP in a 65-year-old male and a 45-year-old female, respectively. Although Kwok *et al.* reported a case of SOP in a patient with influenza B in 2016, that patient also had streptococcal co-infection. All patients showed good responses to steroids. SOP complicating influenza B is rare and only three cases are reported in literature.<sup>2,6,10</sup> Our case is only the fourth case globally and the first such case from India

Our case had various unique features. He had uncontrolled diabetes, as evidenced by his HBA1c and random blood glucose levels which increases the risk of infection. In a study by Shah *et al.*,<sup>13</sup> they found that the risk ratio for hospitalization for infectious disease or mortality due to infectious disease in diabetic patients was 2.17 and 1.92, respectively. Also, the risk of secondary infections is high in influenza. Although no studies relating to secondary infection in Influenza B are available, MacIntyre *et al.*<sup>14</sup> did a systematic analysis to study the prevalence of secondary infections in influenza A. They found that secondary bacterial infection was found in approximately one in four patients and *Pneumococcus* was the most common bacteria identified.<sup>14</sup> So a combination of uncontrolled diabetes and influenza B with the progressive clinical and radiological disease despite treatment made a diagnosis of secondary infection more likely. However, the presence of an “atoll sign” on the repeat CT scan raised the suspicion of organizing pneumonia. In an appropriate clinical setting presence of an atoll sign can be highly specific for organizing pneumonia especially if various infections like invasive fungal infections, bacterial pneumonia, and tuberculosis can be ruled out.<sup>15</sup>

Bronchoscopy in critically ill patients can lead to complications. Hypoxemia is a risk factor for complications during bronchoscopy.<sup>16</sup> Our patient was requiring a FiO<sub>2</sub> of around 50% when he underwent bronchoscopy. Ruling out an infection was essential in our patient as he was at high risk for infections and the use of steroids couldn't be justified without conclusively ruling out infection. We wanted to do a TBLB for the patient as that would have confirmed our clinical suspicion of organizing pneumonia, however, that was not possible due to the patient developing worsening hypoxemia. The partial Pressure of Oxygen (PaO<sub>2</sub>) usually falls by 10 to 20 mm Hg even after uncomplicated bronchoscopy<sup>17</sup> so it was expected in our patient. However, due to the critical nature of intervention in making treatment decisions, it was essential to undertake the same. Our case highlights that in patients with influenza who do not improve despite antiviral therapy, it is important to consider SOP after ruling out complications like secondary infection. Early treatment with corticosteroids is essential for the management of SOP while treatment with corticosteroids is associated with an increased mortality rate in influenza pneumonia. The treatment approaches are diametrically opposite and in cases where both diagnoses seem possible, BAL can help in guiding correct treatment decisions even if the patient's clinical condition precludes performing of lung biopsy.

## References

1. Uyeki TM, Hui DS, Zambon M, et al. Influenza. *Lancet*. 2022;400:693-706.
2. Asai N, Yokoi T, Nishiyama N, et al. Secondary organizing pneumonia following viral pneumonia caused by severe influenza B: a case report and literature reviews. *BMC Infect Dis*. 2017;17:572.
3. Cornejo R, Llanos O, Fernández C, et al. Organizing pneumonia in patients with severe respiratory failure due to novel A

- (H1N1) influenza. *BMJ Case Rep.* 2010;2010:bcr0220102708.
4. Gómez-Gómez A, Martínez-Martínez R, Gotway MB. Organizing pneumonia associated with swine-origin influenza A H1N1 2009 viral infection. *AJR Am J Roentgenol.* 2011;196:W103-4.
  5. He H, Wang H, Li X, et al. Successful management of refractory respiratory failure caused by avian influenza H7N9 and secondary organizing pneumonia: a case report and literature review. *BMC Infect Dis.* 2019;19:671.
  6. Kwok WC, Lam SH, Wong MP, et al. Influenza B/Streptococcal co-infection complicated by organizing pneumonia. *Respirol Case Rep.* 2016;4:e00170.
  7. Liu H, Li J, Chen M, Su J. Glucocorticoid treatment of suspected organizing pneumonia after H7N9 infection: a case report. *Medicine (Baltimore).* 2019;98:e16839.
  8. Nuñez-Conde A, Marquez-Algaba E, Falcó V, et al. Organizing pneumonia secondary to influenza infection: two case reports and a literature review. *Enferm Infecc Microbiol Clin (Engl Ed).* 2020;38:123-6.
  9. Staud R, Ramos LG. Influenza A-associated bronchiolitis obliterans organizing pneumonia mimicking Wegener's granulomatosis. *Rheumatol Int.* 2001;20:125-8.
  10. Shah P, Sobash PT, Vedala K, et al. An uncommon case of Secondary Organizing Pneumonia due to influenza type B. *Clin Pract.* 2021;11:174-7.
  11. Lansbury LE, Rodrigo C, Leonardi-Bee J, et al. Corticosteroids as adjunctive therapy in the treatment of influenza: an updated Cochrane systematic review and meta-analysis. *Crit Care Med* 2020;48:e98-106.
  12. Zhou Y, Fu X, Liu X, et al. Use of corticosteroids in influenza-associated acute respiratory distress syndrome and severe pneumonia: a systemic review and meta-analysis. *Sci Rep* 2020;10:3044.
  13. Shah BR, Hux JE. Quantifying the risk of infectious diseases for people with diabetes. *Diabetes Care.* 2003;26:510-3.
  14. MacIntyre CR, Chughtai AA, Barnes M, et al. The role of pneumonia and secondary bacterial infection in fatal and serious outcomes of pandemic influenza a(H1N1)pdm09. *BMC Infect Dis.* 2018;18:637.
  15. Tendolkar MS, Tyagi R, Mullick G, Chauhan V. A rare case of H1N1 influenza-associated organizing pneumonia. *J Mar Med Soc* 2018;20:165-7.
  16. Ergun B, Nava S. The use of bronchoscopy in critically ill patients: considerations and complications. *Expert Rev Respir Med.* 2018;12:651-63.
  17. Maitre B, Jaber S, Maggiore SM, et al. Continuous positive airway pressure during fiberoptic bronchoscopy in hypoxemic patients. A randomized double-blind study using a new device. *Am J Respir Crit Care Med.* 2000;162:1063-7.