

Sarcoidosis presenting as hoarseness of voice - a rare presentation

Kumar Puskar,¹ Shweta Gupta,¹ Deepak Sharma,² Bhavna Sharma³

¹Department of Respiratory Medicine, Dr. Baba Saheb Ambedkar Medical College and Hospital, Rohini, Delhi; ²Department of Respiratory Medicine, King George Medical University, Lucknow, Uttar Pradesh; ³Department of Pathology, ESI Basaidharapur, Delhi, India

Abstract

We report the case of a 35-year-old woman, presenting with left Vocal Cord Paralysis (VCP). Diagnostic evaluation revealed sarcoidosis to be the underlying pathology. High-resolution Computed Tomography (CT) scans exhibited multiple enlarged right upper and lower paratracheal and prevascular groups of lymph nodes with bilateral diffuse interstitial thickening with ground glass opacities in both lungs. The enlarged lymph nodes

could be a possible mechanism of left vocal cord paralysis through compression of the left recurrent laryngeal nerve. Initial treatment with oral prednisolone (1 mg/kg/day) with subsequent tapering of the dosage led to remission of symptoms. A review of the literature reveals very few cases that have been reported to date, involving the left vocal cord. This is the case, indicating the rarity of sarcoidosis-associated vocal cord paralysis.

Correspondence: Shweta Gupta, Department of Respiratory Medicine, Dr. Baba Saheb Ambedkar Medical College and Hospital, Sector-6, Rohini, Delhi 110085, India.
Tel. +919873817805.
E-mail: docshweta24@rediffmail.com

Key words: cough, hoarseness, prednisolone, sarcoidosis, vocal cords.

Contributions: all the authors made a substantive intellectual contribution. All the authors have read and approved the final version of the manuscript and agreed to be accountable for all aspects of the work.

Conflict of interest: the authors declare no potential conflict of interest.

Funding: none.

Ethics approval and consent to participate: not applicable.

Patient's consent for publication: the patient gave her written consent to use her personal data for the publication of this case report and any accompanying images.

Availability of data and materials: all data generated or analyzed during this study are included in this published article.

Received: 27 August 2024.

Accepted: 28 November 2024.

Early view: 16 December 2024.

This work is licensed under a Creative Commons Attribution-NonCommercial 4.0 International License (CC BY-NC 4.0).

©Copyright: the Author(s), 2024

Licensee PAGEPress, Italy

Chest Disease Reports 2024; 12:12978

doi:10.4081/cdr.2024.12978

Publisher's note: all claims expressed in this article are solely those of the authors and do not necessarily represent those of their affiliated organizations, or those of the publisher, the editors and the reviewers. Any product that may be evaluated in this article or claim that may be made by its manufacturer is not guaranteed or endorsed by the publisher.

Introduction

Sarcoidosis is a multisystemic disease of unknown etiology which often involves multiple organs, most commonly the lungs and lymph nodes.¹ We report an interesting case, which initially presented as hoarseness of voice accompanied by cough and some systemic symptoms such as fatigue and generalized weakness with the presence of multiple enlarged mediastinal lymph nodes with diffuse interstitial thickening with ground glass opacities in the bilateral lung on high-resolution computed tomography of the thorax. Following the diagnosis by transbronchial lung biopsy supported by an elevated serum angiotensin-converting enzyme and exclusion of all the other possible differential diagnosis, the patient was started on corticosteroid therapy with significant improvement in the symptoms and the quality of life of the patient.

Case Report

A 35-year-old female presented with complaints of hoarseness of voice for the last 3 months and shortness of breath (MMRC Grade 1) for the past 2 months. She had no history of fever, cough, loss of weight, or loss of appetite, and she was a non-smoker. Her general physical and respiratory examination was normal. There was no peripheral lymph node on palpation. Her routine blood investigations did not show any abnormality. Chest x-ray was suggestive of fine bilateral reticular opacities. The sputum for direct Acid-Fast Bacilli (AFB) staining and GeneXpert was negative. The Contrast-Enhanced Computer Tomography (CECT) chest revealed diffuse interstitial thickening with surrounding ground glass attenuation in bilateral lung parenchyma and multiple enlarged right upper and lower paratracheal and prevascular lymph nodes (Figure 1 and 2). Serum angiotensin-converting enzyme was 136IU/ml, and other connective tissue serology was negative. Pulmonary function test (spirometry) was suggestive of a restrictive pattern. She was then planned for video-bronchoscopy and conventional Transbronchial Lung Biopsy (TBLB) with Broncho-Alveolar Lavage (BAL). During the procedure, it was noticed that she had a right vocal cord palsy with multiple small nodules on the posterior laryngeal wall (supra-glottic) (Figure 3). All the openings on both sides were normal. BAL was negative for AFB, GeneXpert, and malignant cells, with a predominance of lymphocytes on cytology. The trans-bronchial-lung biopsy from the right lower lobe showed

areas of reticulin fibrosis (Figure 4) with multiple naked granulomas and no evidence of necrosis (Figure 5 and 6), consistent with sarcoidosis. The raised serum ACE levels with the biopsy sample showing non-caseating granulomas established a definitive diagnosis of sarcoidosis. The patient was started on steroid therapy (prednisolone) at the dose of 0.5 mg/kg with tapering of steroid dose every 4 weeks. Her hoarseness and shortness of breath improved significantly after 3 weeks of treatment, and she was advised to stay in regular follow-up.

Discussion

Sarcoidosis is a complex, multisystem, granulomatous disease of unknown aetiology, ranging from asymptomatic to life-threatening manifestations. It commonly involves the lung parenchyma. Laryngeal manifestations of the disease remain rare, with a reported incidence between 0.5% and 8.3%.²

Among the potential laryngeal manifestations, supraglottic and subglottic involvement is usually implicated, with the disease rarely affecting the true vocal cords. Literature has shown there could be three mechanisms for vocal cord paralysis in sarcoidosis. The first mechanism involves direct invasion of the vocal cords by

the granulation tissue. This is very rare as sarcoidosis is mediated through the reticuloendothelial system, and the vocal cords are devoid of any lymphatics. There are few cases reporting direct involvement of the vocal cords, and in those cases, there was involvement of the true vocal cords and supraglottic and subglottic areas, suggesting contiguous spread to the true vocal cords from these areas. The second mechanism is a rare manifestation of sarcoidosis, known as neurosarcoidosis, whereby there is the presence of polyneuritis of the cranial nerves. The third mechanism relates to the compression of the recurrent laryngeal nerves by enlarged mediastinal lymph nodes.³ In our case, it can be both due to direct involvement of the true vocal cords and the supraglottic and subglottic areas as evidenced by the presence of multiple nodules in supraglottic posterior laryngeal wall or due to the involvement of the recurrent laryngeal nerve by the enlarged mediastinal (upper and lower paratracheal) lymph nodes which is the most common mechanism reported for vocal cord paralysis in sarcoidosis. In our case, though the presence of neurosarcoidosis could not be excluded completely, it is very unlikely due to the lack of any aberrant cranial nerve or Central Nervous System (CNS) signs and symptoms. For pulmonary sarcoidosis, systemic glucocorticoids remain the mainstay first-line therapy.^{4,5} As per the consensus statement by the American Thoracic Society, European Respiratory Society, and World Association of Sarcoidosis and Other Granulomatous

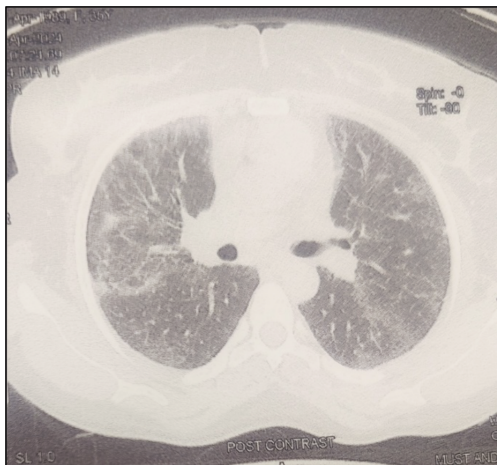


Figure 1. Lung window showing diffuse bilateral interstitial thickening with ground glassing.

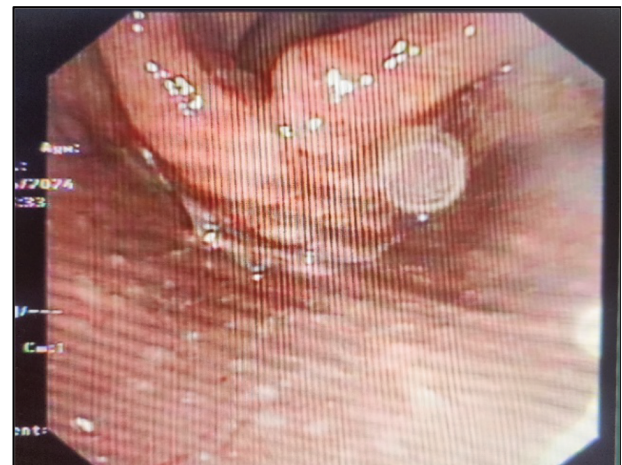

Figure 3. Bronchoscopic view showing multiple nodules.

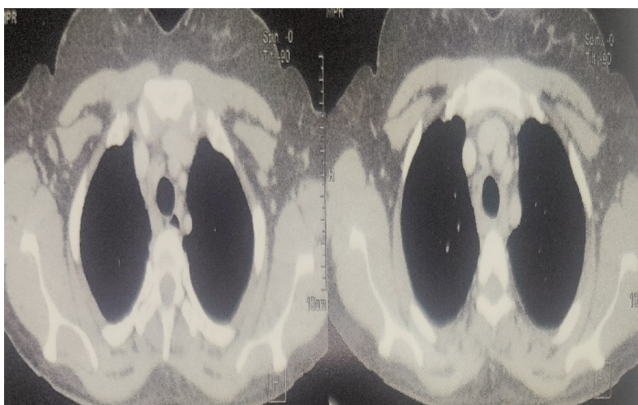


Figure 2. Mediastinal window showing paratracheal lymph nodes.

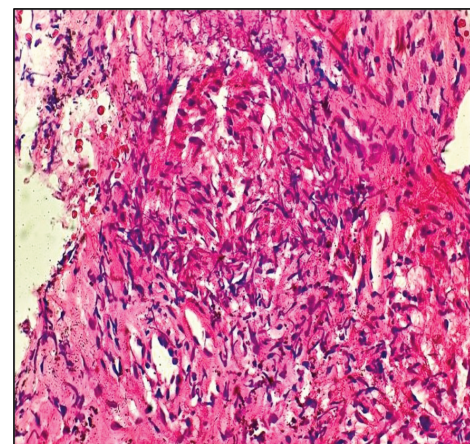


Figure 4. Histopathology image showing areas of reticulin fibrosis.

Disorders, the initial dose is 20–40 mg/day with eventual tapering and discontinuation of therapy in 6-12 months. In some cases, a

maintenance dose is required for a longer duration. Some refractory cases may also require the addition of steroid-sparing agents or biologicals for remission induction.^{6,7} Our patient was initiated on oral steroid (prednisolone) therapy at 0.5 mg/kg/day with a plan to subsequently taper it in 6-12 months. She improved around 3 weeks after starting her therapy with a resolution of hoarseness and shortness of breath.

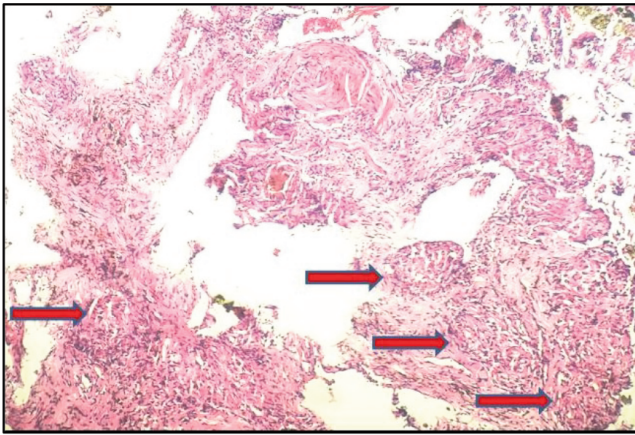


Figure 5. Histopathology image showing lung parenchyma studied with multiple nodular granulomas.

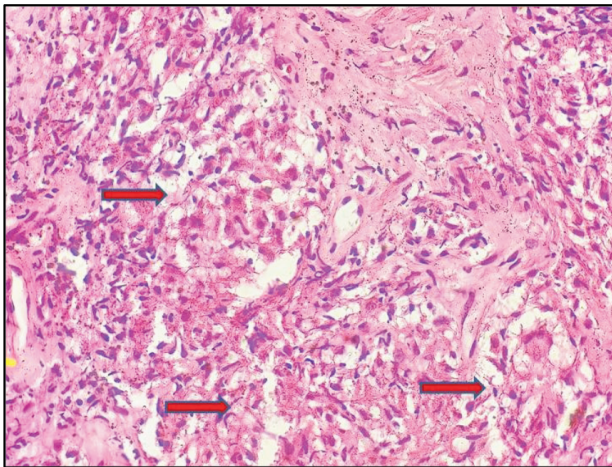


Figure 6. Histopathology image showing multiple naked granulomas.

Conclusions

We conclude that sarcoidosis should be kept in mind as a differential diagnosis of hoarseness of voice. A thorough examination of hoarseness and early initiation of steroid therapy in cases of hoarseness due to sarcoidosis can help us manage the disease better and improve the quality of life of the patient.

References

1. Dean CM, Sataloff RT, Hawkshaw MJ, Pribitkin E. Laryngeal sarcoidosis. *J Voice*. 2002;16:283-8.
2. Lovell L, Clunie GM, Al-Yaghchi C, et al. Laryngeal sarcoidosis and swallowing: what do we know about dysphagia assessment and management in this population? *Dysphagia*. 2022;37:548-57.
3. Raja MHR, Javed MA, Zubairi ABS. Sarcoidosis presenting as vocal cord palsy: an unusual presentation and literature review. *Respirol Case Rep*. 2021;9:e00705.
4. Spalgais S, Thinles T, Mrigpuri P, Kumar R. Pulmonary sarcoidosis presenting as hoarseness and mass lesion. *Monaldi Arch Chest Dis*. 2021;91:1595.
5. Rutt A, Ozgursoy SK. Laryngeal sarcoidosis. *Ear Nose Throat J*. 2021;014556132110125.
6. Subrahmanyam HK, Lee PG RJ. Laryngeal sarcoidosis - a case report. *Case Rep Clin Med*. 2013;02:375-6.
7. Rupanagudi VA, Kanagarajan K, Jayawardena S, et al. Persistent hoarseness of voice in a sarcoid patient: a clue to laryngeal sarcoidosis; a potential cause of upper airway obstruction.