

Yellow bronchoalveolar lavage: a case series and systematic review of the literature

Sanchit Mohan, Rohit Kumar, Pranav Ish, Nitesh Gupta

Department of Pulmonary Medicine, Critical Care and Sleep, Vardhman Mahavir Medical College and Safdarjung Hospital, New Delhi, India

Abstract

Bronchoalveolar Lavage (BAL) is a diagnostic tool that provides pathological and microbiological diagnosis of lower respiratory tract lesions. BAL return may sometimes be of a different color, giving insight into the underlying disease process. Here, we present two cases of yellow BAL fluid with distinct etiologies.

Correspondence: Nitesh Gupta, Department of Pulmonary Medicine, Critical Care and Sleep, Vardhman Mahavir Medical College and Safdarjung Hospital, New Delhi 110027, India.
E-mail: niteshgupta2107@gmail.com

Key words: Bronchoalveolar Lavage (BAL), bronchoscopy, pneumonia, yellow fluid.

Contributions: SM, RK, PI, and NG were involved in the conceptualization, literature search, writing the original draft, literature search, planning, conducting, and editing of the manuscript; SM was involved in the review and editing of the manuscript. NG will act as guarantor on behalf of all authors. All the authors have read and approved the final version of the manuscript and agreed to be held accountable for all aspects of the work.

Conflict of interest: the authors declare no potential conflict of interest.

Funding: none.

Ethics approval and consent to participate: not applicable.

Patient's consent for publication: the patients gave their written consent to use their personal data for the publication of this case report and any accompanying images.

Availability of data and materials: all data generated or analyzed during this study are included in this published article.

Received: 23 August 2024.

Accepted: 14 November 2024.

Early view: 19 November 2024.

This work is licensed under a Creative Commons Attribution-NonCommercial 4.0 International License (CC BY-NC 4.0).

©Copyright: the Author(s), 2024

Licensee PAGEPress, Italy

Chest Disease Reports 2024; 12:12960

doi:10.4081/cdr.2024.12960

Publisher's note: all claims expressed in this article are solely those of the authors and do not necessarily represent those of their affiliated organizations, or those of the publisher, the editors and the reviewers. Any product that may be evaluated in this article or claim that may be made by its manufacturer is not guaranteed or endorsed by the publisher.

Introduction

Bronchoalveolar Lavage (BAL) is a technique to sample cellular or acellular components of lower airways, providing significant insights into the pathological processes affecting the lower respiratory tract. The appearance and analysis of BAL fluid can reveal crucial information regarding infectious and inflammatory conditions within the lungs.¹ BAL may be diagnostic for Diffuse Alveolar Hemorrhage (DAH), which shows sequential hemorrhagic aliquot return, and Pulmonary Alveolar Proteinosis (PAP), which shows a milky white return.¹ Yellow BAL fluid often signals the presence of pus, suggesting an underlying infection or significant inflammation, and necessitates comprehensive microbiological and cytological evaluation.²

The current study aims to illustrate the diagnostic challenges and considerations when encountering yellow BAL fluid in the clinical setting.

Case Report

Case 1

A 19-year-old male presented with complaints of dry cough, sporadic right-sided chest pain, and lethargy for two months. The patient's medical history was unremarkable for fever, weight loss, or night sweats. The patient's laboratory tests were unremarkable except for the Erythrocyte Sedimentation Rate (ESR), which was significantly elevated (ESR-80 mm/hr). Contrast-Enhanced Computed Tomography (CECT) of the thorax highlighted consolidation in the posterior segment of the right upper lobe (Figure 1a). BAL yielded a yellow fluid on every successive return (Figure 1b). The cytological examination revealed abundant neutrophils and macrophages, but atypical cells were absent. Gram and KOH stains were negative, and the Acid-Fast Bacilli (AFB) stain showed the presence of acid-fast bacilli. Cartridge-Based Nucleic Acid Amplification Testing (CBNAAT) showed *Mycobacterium tuberculosis* (MTB) detected high, and rifampicin resistance was not detected. Aerobic and fungal cultures were negative. The patient was diagnosed with pulmonary tuberculosis and was initiated on Anti-Tubercular Therapy (ATT) under the National Tuberculosis Elimination Programme³ (NTEP) and showed clinical and radiological response to therapy.

Case 2

A 13-year-old female was hospitalized due to fever, dry cough, and dyspnea modified Medical Research Council (mMRC) grade 2 for two weeks. Laboratory investigations were unremarkable, except Complete Blood Counts (CBC) showed a total leukocyte count of 24000/cu mm (4000-10000/ccu mm) and raised procalcitonin levels 13 ng/mL (<0.05 ng/ml). CECT of the thorax revealed bulky necrotic mediastinal lymph nodes bilateral hilar and subcari-

nal region, the largest measuring 2.8 cm in the long axis at the sub-carinal region, multiple solid nodules in the superior segment of bilateral lower lobes along with Ground Glass Opacities (GGOs), the largest nodule measuring 3 cm in diameter in the superior segment of right lower lobe areas of GGO were also seen in the right middle and lingular lobe (Figure- 2a, 2b). BAL from the superior segment of the right lower lobe produced a yellow fluid on every successive return (Figure 2c). The cytological examination revealed

numerous neutrophils, but there was no evidence of malignancy. AFB and KOH stains were negative, and the gram stain showed the presence of grape-like cocci-shaped cells. CBNAAT showed that MTB were not detected. AFB and fungal cultures were negative. The culture of the BAL fluid showed the presence of yellowish colonies of Methicillin-Resistant *Staphylococcus aureus* (MRSA) on blood agar. The patient did not have any comorbidities, and there was no history of- hospitalization in the past, lung or renal disease,

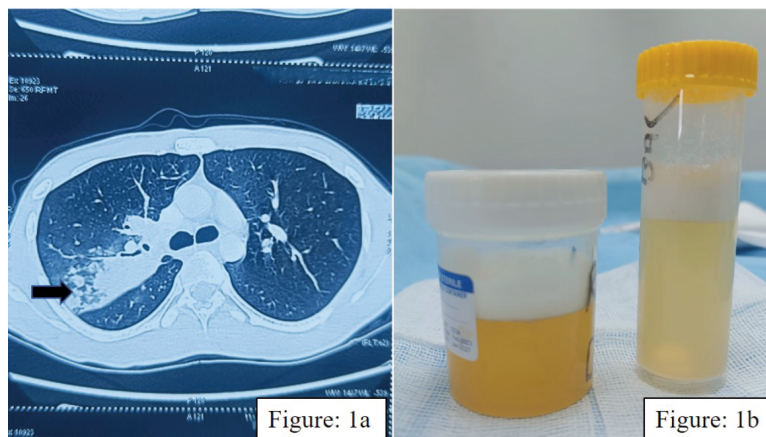


Figure 1. a) Black thick arrow shows right upper lobe consolidation; b) the picture shows golden yellow Bronchoalveolar Lavage (BAL) fluid.

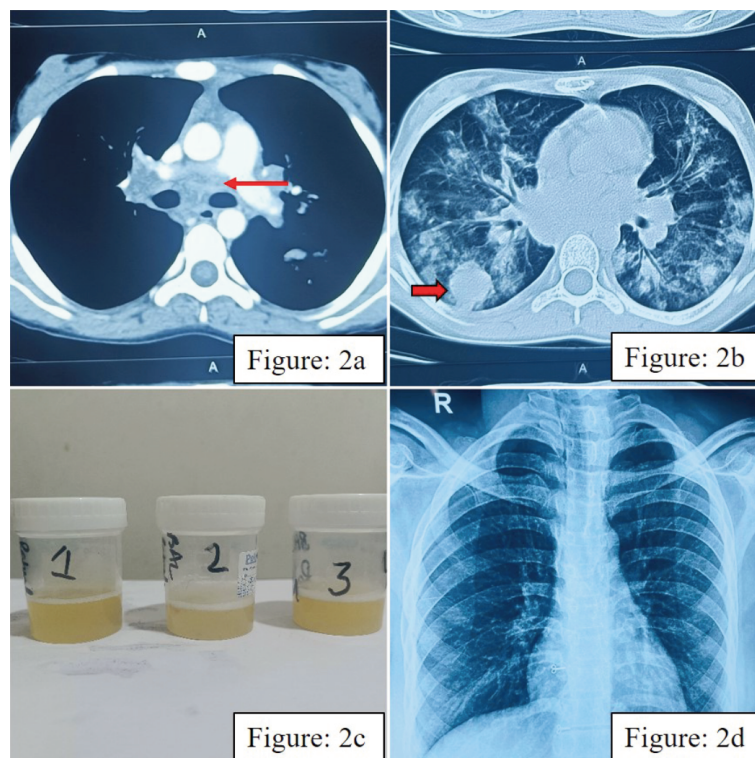


Figure 1. a) (Red thin arrow) showing necrotic mediastinal lymphadenopathy; b) (red thick arrow) showing right lower lobe nodule of size 3 cm with multiple nodules along with Ground Glass Opacity (GGO) in bilateral lungs; c) golden yellow Bronchoalveolar Lavage (BAL) fluid; d) chest X-ray of the patient after 2 weeks showing resolution.

drug abuse, or history of immunosuppressive therapy. The serology for Human Immunodeficiency Virus (HIV) was non-reactive, echocardiography of the heart did not show any evidence of infective endocarditis. The diagnosis of MRSA pneumonia was made, and she was treated with linezolid 600 mg for 7 days; a significant radiological response was seen in chest radiography done after 2 weeks (Figure 2d).

Discussion

These cases highlight that yellow BAL fluid can arise from various etiologies, even in young patients without underlying comorbid conditions. While both patients presented with yellow BAL fluid, the underlying causes were distinct. Both cases in the present study had an infectious etiology for yellow BAL fluid.

The literature suggests the cause of the yellow-colored BAL fluid is the profound exudation of plasma fluid into alveoli.⁴ The present cases had high cell counts. One had numerous neutrophils and macrophages, and the other had predominantly neutrophils.

The systematic review of the literature on yellow BAL yielded results in two broad categories: Infectious and Inflammatory. Infectious causes are due to bacterial pneumonia,² cystic fibrosis, invasive or allergic broncho-pulmonary aspergillosis, histoplasmosis or coccidioidomycosis, and *Strongyloides* leading to eosinophilic pneumonia.⁵ Inflammatory causes are hypersensitivity pneumonitis,⁶ aspiration pneumonitis, chronic bronchitis, lung cancer causing obstruction leading to secondary infection, cryptogenic organizing pneumonia,⁴ lipoid pneumonia, eosinophilic pneumonia,^{7,8} diffuse alveolar hemorrhage.⁹ Hemorrhage into the alveolar spaces might initially appear red or pink, but after a period, blood breakdown products can give a yellowish hue.⁹ Among inflammatory causes, eosinophilic pneumonia is more commonly associated with yellow BAL due to the high amount of eosinophilic cationic proteins in BAL fluid.^{7,8}

A case series published by Contou *et al.*¹⁰ showed that three patients with sickle cell disease admitted for acute chest syndrome with severe respiratory failure requiring mechanical ventilation had yellowish BAL fluid. The cell count of the BAL fluid showed 30% macrophages and was positive for oil red O stain, indicating fat embolism. However, in the present cases, the BAL fluid of the first case had numerous neutrophils and macrophages, and the second case had neutrophilic exudate.

Conclusions

In conclusion, the diagnostic approach to yellow BAL fluid must be comprehensive and systematic, considering various potential causes. Despite the common appearance of the BAL fluid, the underlying causes - tuberculosis in one patient and bacterial pneumonia in the other - highlight the diverse etiologies that can present similarly. The above cases highlight that detailed diagnostic workup for BAL samples, including microbiological, cytological, and imaging studies, are required to confirm the diagnosis.

References

1. Costabel U. Atlas of bronchoalveolar lavage. CRC Press; Boca Raton, USA; 1998.
2. Facciolongo N, Puglisi S, Menzella F, et al. The role of bronchoalveolar lavage in the diagnosis of infectious diseases: a focus on community-acquired pneumonia. *Respiratory Medicine*. 2012;106:1-9.
3. Khanna A, Saha R, Ahmad N. National TB elimination program - What has changed. *Indian J Med Microbiol*. 2023;42:103-7.
4. Inui T, Shibagaki A, Kawashima K, et al. Golden-yellow bronchoalveolar lavage fluid in acute fibri-nous and organizing pneumonia. *Respir Endosc*. 2023;1:101-4.
5. Nutman TB. Human infection with *Strongyloides stercoralis* and other related *Strongyloides* species. *Parasitology*. 2017;144:263-73.
6. Lacasse Y, Selman M, Costabel U, et al. Clinical diagnosis of hypersensitivity pneumonitis. *American Journal of Respiratory and Critical Care Medicine*. 2009;179: 932-8.
7. Nabeya D, Kinjo T, Miyagi K, Fujita J. Yellow broncho-alveolar lavage fluid in eosinophilic pneumonia. *Intern Med*. 2016;55:3227-8.
8. Martyn K, Lyons O, Blazer A. Yellow bronchoalveolar lavage from chronic eosinophilic pneumonia. *Canadian Journal of Respiratory, Critical Care, and Sleep Medicine*, 2024;8:192-3.
9. Collard HR, Schwarz MI. Diffuse alveolar hemorrhage. *Clinics in Chest Medicine*. 2007;25:583-92.
10. Contou D, Mekontso Dessap A, Carteaux G, et al. Golden tracheal secretions and bronchoalveolar fluid during acute chest syndrome in sickle cell disease. *Respir Care*. 2015;60:e73-5.