

Kikuchi lymphadenitis, a rare case: an overview of its clinical presentation, diagnostic challenges, and therapeutic approaches

Karuna Sree Alwa,¹ Srinivas Reddy Kallem,² Mahesh Babu Vemuri,¹ Saahil Kumar,¹ Ashutosh Rath³

¹Pulmonary Medicine, All India Institute of Medical Sciences (AIIMS), Bibinagar; ²General Surgery, All India Institute of Medical Sciences (AIIMS), Bibinagar; ³Pathology, All India Institute of Medical Sciences (AIIMS), Bibinagar, India

Abstract

Kikuchi-Fujimoto Disease (KFD), also known as histiocytic necrotizing lymphadenitis, is a rare, self-limiting condition typically presenting with lymphadenopathy and fever. The etiology remains unclear, but it is thought to be associated with viral infections and autoimmune processes. We report a case of a female who presented with cervical lymphadenopathy. An excisional biopsy of the lymph node was performed, showing characteristic histopathological features of KFD. Based on the clinical presentation and histopathological findings, a diagnosis of Kikuchi-

Fujimoto disease was made. The patient was managed with supportive care, including antipyretics and Non-Steroidal Anti-Inflammatory Drugs (NSAIDs). No antibiotics or corticosteroids were administered. The patient's symptoms gradually resolved over a period. Follow-up at three months revealed the resolution of symptoms with no recurrence. The patient remained asymptomatic at subsequent visits. KFD should be considered in young patients presenting with fever and lymphadenopathy. Diagnosis is confirmed through lymph node biopsy demonstrating characteristic histopathological features. The disease typically follows a benign course with spontaneous resolution, and management is primarily supportive.

Correspondence: Karuna Sree Alwa, Pulmonary Medicine, All India Institute of Medical Sciences (AIIMS), Bibinagar, India.
E-mail: drkarunareddy04@gmail.com

Key words: Kikuchi lymphadenitis, Kikuchi-Fujimoto lymphadenitis.

Contributions: all the authors made a substantive intellectual contribution. All the authors have read and approved the final version of the manuscript and agreed to be held accountable for all aspects of the work.

Conflict of interest: the authors declare no potential conflict of interest.

Funding: none.

Ethics approval and consent to participate: not applicable.

Patient's consent for publication: the patient gave her written consent to use her personal data for the publication of this case report and any accompanying images.

Availability of data and materials: all data generated or analyzed during this study are included in this published article.

Received: 23 July 2024.

Accepted: 10 September 2024.

Early view: 25 October 2024.

This work is licensed under a Creative Commons Attribution-NonCommercial 4.0 International License (CC BY-NC 4.0).

©Copyright: the Author(s), 2024
Licensee PAGEPress, Italy
Chest Disease Reports 2024; 12:2835
doi:10.4081/cdr.2024.12835

Publisher's note: all claims expressed in this article are solely those of the authors and do not necessarily represent those of their affiliated organizations, or those of the publisher, the editors and the reviewers. Any product that may be evaluated in this article or claim that may be made by its manufacturer is not guaranteed or endorsed by the publisher.

Introduction

Kikuchi-Fujimoto Disease (KFD), first described by Japanese pathologists Kikuchi and Fujimoto in 1972, has a worldwide distribution with a higher prevalence among Japanese and other Asian individuals. Histopathological examination of the lymph nodes in KFD can show extensive necrotizing inflammation and histiocytosis in the cortical and paracortical regions. KFD is a benign, self-limiting cervical lymphadenitis of unknown etiology. Young women are affected predominantly and it can closely mimic infective and immunological disorders.

Case Report

A 21-year-old female came with complaints of multiple swellings in the right side of her neck for two months, increasing gradually associated with pain. The patient had a history of fever for three days. There was no weight loss. There was no previous history of tuberculosis or contact with tuberculosis. She did not have a history of any drug intake or atopy. She did not have any other significant medical problems.

On examination, the wound appeared healthy with no discharge or gap. Clinical examination revealed extensive, mobile, and tender cervical lymphadenopathy on the right side, the larger node being the supraclavicular lymph node, which measured about 3x2 cm. There were no palpable lymph nodes elsewhere. The blood pressure was 120/90 mm Hg, and the pulse rate was 98/min. Her cardiovascular, respiratory, and neurological examinations were normal. Skin and throat examinations were also normal. White Blood Cell count (WBC) was slightly low, 3.42×10^9 L. Renal and liver function test results were within normal limits.

Serum Lactate Dehydrogenase (LDH) was 234 U/L (elevated). Blood and urine cultures were negative. Montoux showed an induration of 4 mm. Ultrasound of the abdomen and Chest radiograph were normal. Antinuclear Antibody (ANA) and anti-DNA antibody were negative. Staining for Acid-Fast Bacilli (AFB) was also negative. An ultrasound of the neck revealed multiple enlarged lymph nodes in the right cervical region, conglomerate in appearance, and the largest measuring 9 mm.

The Fine Needle Aspiration Cytology (FNAC) of the lymph node smear showed a polymorphous lymphoid population at varying stages of maturation, including small lymphocytes, centrocytes, centroblasts, and a few immunoblasts. Tangible body macrophages were also observed. The impression was suggestive of reactive lymphadenitis. FNAC showed features suggestive of reactive lymphadenitis, and the patient was started on oral antibiotics. Since the patient continued to have a fever and persistent lymphadenopathy, despite one week of antibiotics, a lymph node biopsy was done, and the histological features suggested the diagnosis of KFD. Histopathological Examination (HPE) revealed patchy necrosis with surrounding karyorrhectic debris and macrophages, consistent with necrotizing histiocytic lymphadenitis (KFD) (Figure 1). The patient was treated with Non-Steroidal Anti-Inflammatory Drugs (NSAIDs) symptomatically, and the lymph nodes regressed in four weeks. The patient was advised to regularly follow up for any complications.

Discussion

KFD is characterized by necrotizing lymphadenitis, predominantly affecting cervical lymph nodes. It mostly occurs in patients in Asia; the exact incidence remains unclear as many cases are easily mistaken for other causes of lymphadenopathy.¹ Alexandre *et al.* presented three cases of cervical lymphadenopathy and hoped that the diagnosis suggested necrotizing histiocytic lymphadenitis, which is similar to our case.² The aetiology of KFD is unknown, and the two most possible theories hypothesised regarding aetiology are infectious and autoimmune. The possible etiologic agents of KFD are Epstein-Barr virus, herpes simplex virus, varicella-zoster virus, human herpesviruses 6, 7, and 8, parvovirus B19, human immunodeficiency virus, human T-lymphotropic virus type 1, paramyxovirus; parainfluenza virus; rubella; cytomegalovirus; hepatitis B virus; and dengue virus.³⁻⁵ KFD has also been reported with autoimmune diseases like Systemic Lupus Erythematosus (SLE), hemophagocytic disease, polymyositis, Sjogren's Syndrome, and relapsing polychondritis.³ An increase in lactate dehydrogenase, C-reactive protein, and aminotransferase was also noticed in a few subjects, which is similar to the findings of many other studies.

KFD is usually diagnosed on the basis of an excision biopsy of affected lymph nodes. Histology of the lymph nodes in KFD shows paracortical expansion with foci of incipient necrosis laden with karyorrhectic debris both within and outside macrophages.⁴ Fine Needle Aspiration (FNA) is a well-established procedure for the diagnosis of lymphadenitis, but in KFD, inadequate specimens and false-negative cytological readings are frequently encountered. A study conducted by San Chi Yu *et al.* compared open biopsy and guided core biopsy, and they recommended open biopsy as a diagnostic tool for KFD.⁵ In a study conducted by Hitender Goutam *et al.*, which involved 140 patients with tuberculous lymphadenitis, fever was the most common systemic symptom.^{1,2} Similarly, in KFD, fever is the most common systemic symptom. On fine needle aspiration cytology, coagulative necrosis is the feature commonly observed in KFD, as well as tubercular lymphadenitis. In our case series, both patients were initially diagnosed as cases of tubercular lymphadenitis based on clinical as well as cytological features and given a course of Anti-Tuberculosis Treatment (ATT).⁶ KFD presents very similar to tubercular lymphadenitis both clinically and pathologically. The cervical lymph node is the most common site of involvement in tuberculosis, with more prevalence among females, which is a more similar presentation to KFD.^{1,2} In our case, the patient was initially diagnosed with tubercular lymphadenitis. Based on clinical, there was no improvement with treatment, so we went for a biopsy and diagnosed it as KFD.³

Conclusions

This case highlights the clinical and histopathological features of KFD. Recognition of this condition is crucial for appropriate management and to avoid unnecessary intervention. KFD is a rare, benign disease that mainly occurs in young women. The clinical presentation of KFD can vary, often resembling other diseases, and its imaging features are non-specific. Diagnosis should be considered in young women who present with short-term cervical lymphadenopathy. Long-term follow-up is essential to monitor these patients for the development of autoimmune diseases or recurrence of KFD.

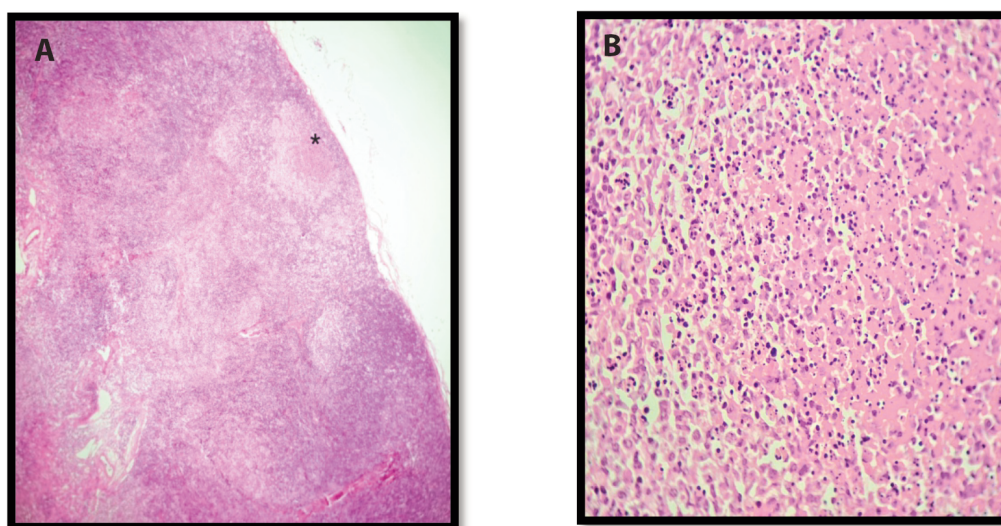


Figure 1. A) Low power view of lymph node showing partial effacement of the nodal architecture by necrosis (*) and histiocytic infiltrate (x40, HE). **B)** Necrosis with histiocytic infiltrate and nuclear debris. Note the absence of neutrophils (x400, HE).

References

1. Hoan L, Minh Hang L, Tuan Linh L, et al. A rare case of Kikuchi-Fujimoto disease in a young female patient. *Am J Case Rep.* 2021;22:e9333771-5.
2. Sousa ADA, Soares JMA, Santos MHDS, et al. Kikuchi-Fujimoto disease: three case reports. *Sao Paulo Med J.* 2010;128:232-5.
3. Mallick A, Mohapatra MM, Babu VM, et al. All necrotizing nodes are not tuberculosis - A report of two cases. *Indian J Tuberc.* 2022;69:695-8.
4. Rakesh P, Alex RG, Varghese GM, et al. Kikuchi-Fujimoto disease: clinical and laboratory characteristics and outcome. *J Glob Infect Dis.* 2014;6:147-50.
5. Yu SC, Chen CN, Huang HI, et al. Diagnosis of Kikuchi-Fujimoto disease: a comparison between open biopsy and minimally invasive ultrasound-guided core biopsy. *PLOS ONE.* 2014;9:e95886.
6. Gautam H, Agrawal SK, Verma SK, Singh UB. Cervical tuberculous lymphadenitis: clinical profile and diagnostic modalities. *Int J Mycobacteriology.* 2018;7:212-6.