

# A rare case of community-acquired pneumonia complicated by severe acute respiratory distress syndrome in an immunocompetent male: *Aeromonas jandaei*

Jayabharathi Palanivel, Pratap Upadhya, Madhusmita Mohanty Mohapatra, Prateek Bagarhatta, Mounicka Karthikeyan

Department of Pulmonary Medicine, Jawaharlal Institute of Postgraduate Medical Education and Research, Pondicherry, India

## Abstract

*Aeromonas jandaei* is an oxidase-positive Gram-Negative (GN) motile rod and is usually found in aquatic environments. It is commonly associated with gastrointestinal infections, wound

infections, and septicemia. While species like *A. veronii* and *A. hydrophila* are known to cause pneumonia, we report a rare incidence of severe pneumonia complicated by Acute Respiratory Distress Syndrome (ARDS) caused by *A. jandaei*, highlighting the challenges in diagnosing and managing infections caused by rare, multidrug-resistant pathogens. This report describes a case of pneumonia caused by *Aeromonas jandaei*, a bacterium previously less documented in respiratory infections.

Correspondence: Mounicka Karthikeyan, Department of Pulmonary Medicine, Jawaharlal Institute of Postgraduate Medical Education and Research, Puducherry, India.  
Tel. +919489023599.  
E-mail: mounickakarthikeyan@gmail.com

Key words: *Aeromonas jandaei*, ARDS, multidrug-resistant pathogen, immunocompetent patient.

Contributions: the conception and design of the study, acquisition of data, analysis, and interpretation of data were done by MK, JP, PU, MMM, PB. The drafting of the article or revising it critically for important intellectual content were done by JP, PU. All the authors have read and approved the final version of the manuscript and agreed to be accountable for all aspects of the work.

Conflict of interest: the authors declare no potential conflict of interest.

Funding: none.

Ethics approval and consent to participate: not applicable.

Informed consent: the patient's relatives gave their written consent to use his personal data for the publication of this case report and any accompanying images.

Availability of data and materials: all data underlying the findings are fully available.

Received: 5 July 2024.

Accepted: 5 August 2024.

Early view: 5 September 2024.

This work is licensed under a Creative Commons Attribution-NonCommercial 4.0 International License (CC BY-NC 4.0).

©Copyright: the Author(s), 2024

Licensee PAGEPress, Italy

Chest Disease Reports 2024; 12:12788

doi:10.4081/cdr.2024.12788

*Publisher's note: all claims expressed in this article are solely those of the authors and do not necessarily represent those of their affiliated organizations, or those of the publisher, the editors and the reviewers. Any product that may be evaluated in this article or claim that may be made by its manufacturer is not guaranteed or endorsed by the publisher.*

## Introduction

*Aeromonas* species are Gram-Negative (GN) bacilli found ubiquitously in fresh and brackish water habitats. These bacteria are facultatively anaerobic, non-sporulating, carbohydrate fermenters, and beta-hemolytic on a blood agar culture.<sup>1,2</sup> Initially classified within the family Vibrionaceae, *Aeromonas* has been reclassified based on subsequent phylogenetic analyses.<sup>2</sup> It is more commonly associated with gastrointestinal infections, wound infections, meningitis, peritonitis, and septicemia.<sup>3</sup> While species like *A. veronii* and *A. hydrophila* are known to cause pneumonia, *Aeromonas jandaei*, an opportunistic bacterium, rarely causes respiratory infections like community-acquired pneumonia in an immunocompromised individual.<sup>4</sup>

*Aeromonas* species are uniformly resistant to commonly used antibiotics such as ampicillin, ceftriaxone, imipenem, piperacillin, and ticarcillin.<sup>5</sup> This resistance is mediated through various Antimicrobial Resistance (AMR) strategies, including efflux pumps, inhibition of drug uptake, and horizontal gene transfer, making infections difficult to treat.<sup>6</sup> In this report, we present a rare case of severe Acute Respiratory Distress Syndrome (ARDS) caused by *Aeromonas jandaei* in a previously healthy, immunocompetent adult, highlighting the importance of awareness regarding this organism as a respiratory pathogen, its resistance patterns, and the appropriate management of such rare pathogens.

## Case Report

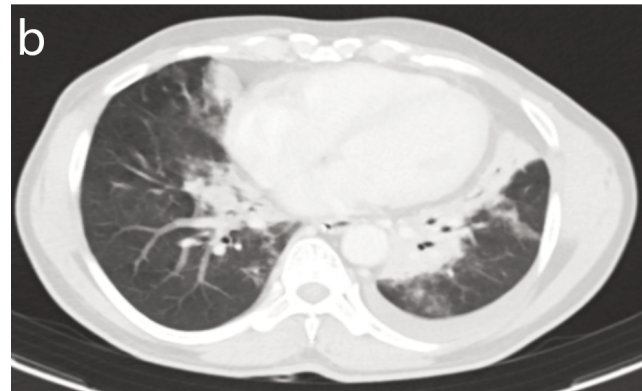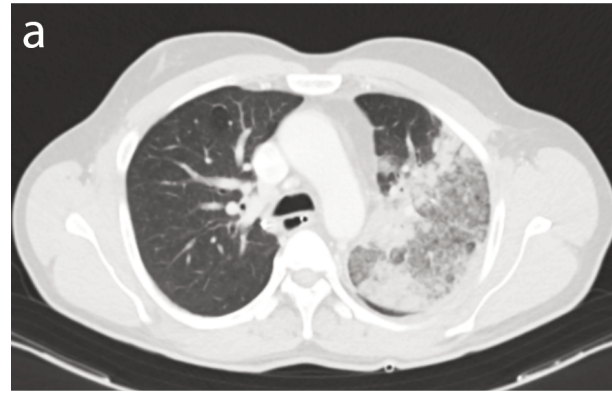A 52-year-old male well-digger with a history of bronchial asthma for 20 years on irregular inhalers and chronic hepatitis B infection treated with tenofovir disoproxil fumarate for 9 years presented to the emergency department at a private hospital with a history of fever associated with chills for 5 days, shortness of breath for 2 days which was acute in onset, which had progressed from Modified Medical Research Council (mMRC) grade I to IV in 2 days. Later, due to worsening respiratory failure, he was referred to our center on the same day. He had no history of previous stroke, diabetes, or hypertension. Family members didn't give any history of recent drowning. On arrival, the patient was afebrile, conscious, and oriented. On initial assessment, the indi-

vidual had tachypnea (30 breaths per minute), tachycardia (104 beats per minute), hypotension (80/60 mmHg; Mean Arterial Pressure, MAP, 67 mmHg), and a Room Air Oxygen Saturation ( $SpO_2$ ) of 89%. Initial Arterial Blood Gas (ABG) analysis showed type I hypoxemic respiratory failure with a  $PaO_2/FiO_2$  ratio of 285. Chest X-ray showed left-sided heterogeneous opacities in upper and mid zones with left costophrenic angle blunting (Figure 1). Point-of-care ultrasound demonstrated normal left ventricular ejection fraction, Inferior Vena Cava (IVC) with >50% respiratory variability, and a left upper lobe C profile with minimal pleural effusion consistent with pneumonia.

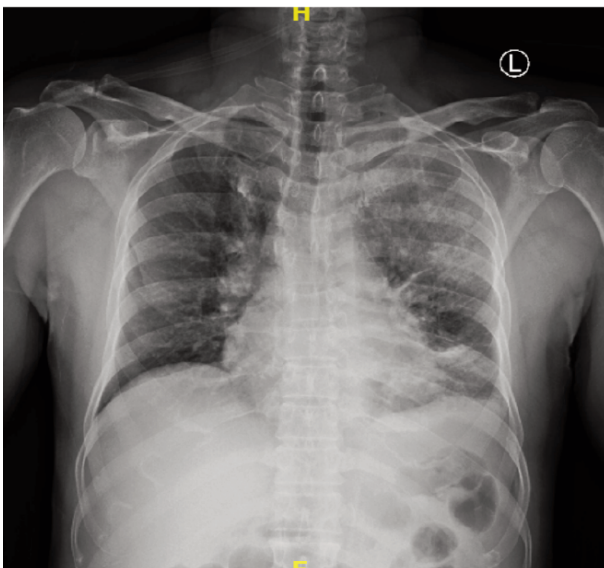
The patient was empirically started on intravenous ceftriaxone and azithromycin suspecting Community-Acquired Pneumonia (CAP) as per intensive care protocol in India.<sup>7,8</sup> Hypotension resolved with initial intravenous fluid resuscitation suggesting hypovolemic shock. The patient was transferred to the Respiratory Intensive Care Unit (RICU) for further management.

Routine blood and sputum cultures were obtained. Ultrasound (USG) guided diagnostic thoracentesis was performed from left mild pleural effusion and 40 mL of brownish fluid was aspirated. Laboratory parameters revealed a white blood cell count of  $15500/mm^3$  (normal range  $4000-11000/mm^3$ ), hemoglobin level and platelet count were normal. Liver and renal function parameters were within the normal range. Paired blood cultures were reported sterile, but serum procalcitonin was elevated (14.6 ng/mL; normal  $<0.05$  ng/mL).

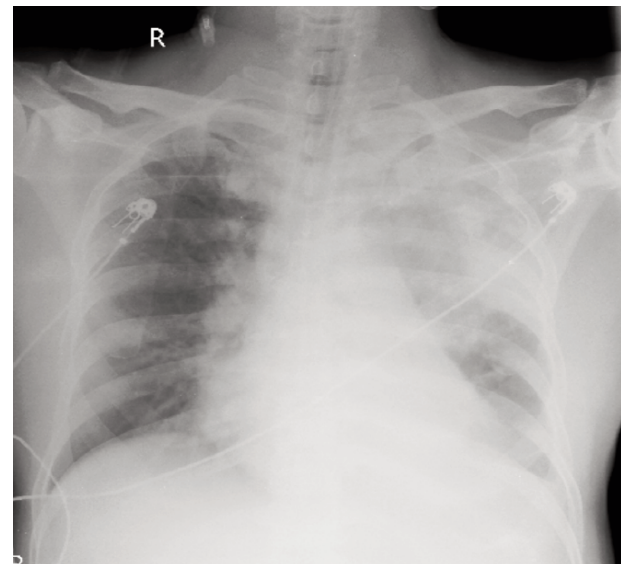
A Computed Tomography Pulmonary Angiogram (CTPA) was performed given persistent tachycardia and worsening hypoxemic respiratory failure with a  $PaO_2/FiO_2$  ratio of 167. The patient's CT imaging results revealed no evidence of pulmonary thromboembolism. The CT scan demonstrated left upper lobe consolidation and surrounding ground-glass opacities with interlobar septal thickening, and bilateral lower lobe perihilar consolidation with minimal effusion was also noted, the imaging findings were consistent with ARDS, likely caused by an infectious etiology given the short history and fever (Figure 2). Chest radiography also showed an increase in heterogeneous opacities in the left upper,



**Figure 2.** a) Computed Tomography Pulmonary Angiogram (CTPA) of the thorax (axial view) showing left upper lobe consolidation with surrounding ground glass opacities (suggested by arrows) and interlobar septal thickening. b) CTPA with axial view showing bilateral lower lobe perihilar consolidation with left minimal effusion consistent with acute respiratory distress syndrome.



**Figure 1.** Chest radiography posteroanterior view taken on day 1 of admission showing heterogenous opacity in the left upper and mid-zone with costophrenic angle blunting consistent with pneumonia.



**Figure 3.** Chest radiography posteroanterior view showing an increase in heterogeneous opacities in left, upper, mid zone, and lower zone with left side costophrenic angle blunting indicating rapid progression.

mid and lower zone with left-side costophrenic angle blunting (Figure 3). Notably, a previous CT scan performed the day before at an outside hospital showed consolidation limited to the apical-posterior segment of the left upper lobe, indicating rapid deterioration of the patient's condition. The antibiotic was escalated to meropenam considering the severity of pneumonia and the patient was intubated and placed on volume-assist controlled mechanical ventilation. Sedation and paralysis were administered as per the ARDSnet trial.<sup>9</sup> The designated settings included a tidal volume of 420 mL (6 mL per kg ideal body weight), Positive End-Expiratory Pressure (PEEP) set at 10 cm H<sub>2</sub>O, a respiratory rate at 30/min, and FiO<sub>2</sub> at 45%, P plateau constantly maintained below 30 cm H<sub>2</sub>O. A Pressure-Volume (PV) tool was implemented manually to assess PEEP responsiveness, and subsequent adjustments were made accordingly. Sputum pyogenic culture, fungal cultures, Acid Fast Bacilli (AFB) smear, Cartridge-Based Nucleic Acid Amplification Technique (CBNAAT) for *Mycobacterium tuberculosis* (MTB) and COVID-19, influenza, Reverse Transcription Polymerase Chain Reaction (RT-PCR) testing were all negative. Pleural fluid analysis confirmed an exudative, neutrophilic effusion with an Adenosine Deaminase (ADA) level of 38.2 U/L. Pleural fluid cultures and CBNAAT for MTB were negative.

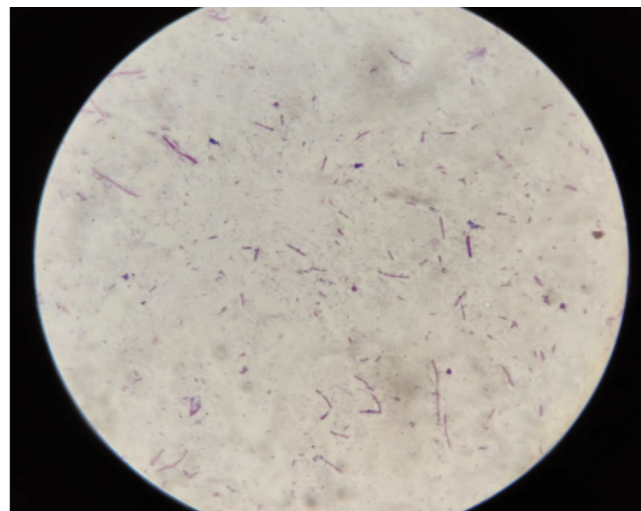
On day 2 of admission, oseltamivir was added for viral coverage because of worsening oxygen requirement with a p/f ratio of around 108. Mini Bronchoalveolar Lavage (BAL) was performed as sputum cultures were sterile and sent for pyogenic culture which grew multi-drug resistant *Aeromonas jandaei* (Figure 4) identified by Matrix-Assisted Laser Desorption/Ionization-Time of Flight (MALDI-TOF) mass spectrometry technique. The sensitivity report indicated resistance to ceftriaxone, piperacillin-tazobactam, and meropenam, while the organism was sensitive to sensitive to amikacin, levofloxacin, and trimethoprim-sulfamethoxazole (Table 1). Despite treatment efforts, the patient's condition did not improve, on the third day of admission, he succumbed to severe ARDS and respiratory failure. A post-mortem lung biopsy subsequently confirmed the presence of bronchopneumonia changes (Figure 5).

## Discussion

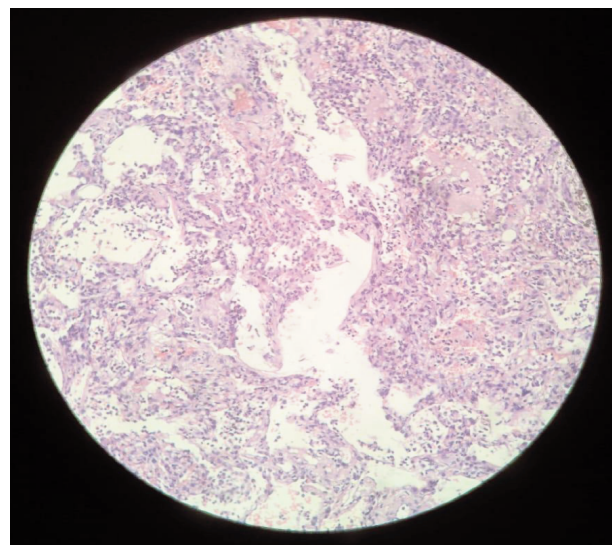
The first documented human *Aeromonas* infection was reported in 1951 when the organism was isolated from cerebral spinal fluid during an autopsy in Jamaica.<sup>8</sup> Since then, the genus has expanded to include 36 species, with 19 identified as emerging human pathogens. *A. jandaei*, named after J. Michael Janda was first isolated in the USA in 1991 from clinical samples such as blood, wounds, and stools.<sup>1</sup>

*Aeromonas hydrophila* is the most commonly implicated species in human infections, although rare cases of *A. caviae* and *A. sobria* have been reported, particularly in burn patients, where

infections are associated with high mortality rates.<sup>10</sup> *A. jandaei*, isolated in our case, has traditionally been associated with skin, soft tissue, and gastrointestinal diseases. To our knowledge, this is the first reported instance of *A. jandaei* causing ARDS in an immunocompetent individual.



**Figure 4.** Gram staining of mini bronchoalveolar lavage showing gram-negative rods.



**Figure 5.** Post-mortem biopsy of left lung showing alveolar dilation with focal congestion in intra alveolar as well as interstitial neutrophilic infiltration suggestive of bronchopneumonia.

**Table 1.** Antimicrobial sensitivity pattern of *Aeromonas jandaei* isolated in our case.

ANTIBIOTIC	MIC dilution (µg/mL)	MIC interpretation
Ceftriaxone	4	Resistant
Piperacillin tazobactam	>128	Resistant
Meropenem	>16	Resistant
Ciprofloxacin	<0/06	Sensitive
Amikacin	8	Sensitive
Cotrimoxazole	<8	Sensitive

MIC, Minimum Inhibitory Concentration.

Risk factors for *Aeromonas* infection include immunocompromised states and exposure to environmental water or soil sources.<sup>11</sup> The gastrointestinal tract serves as the primary portal of entry. Soft tissue infections, including necrotizing infections, have been documented following contamination of open wounds with soil. *A. hydrophila* has also been identified in pneumonia cases associated with near-drowning incidents with reported mortality as high as 50%.<sup>4</sup> Our patient's occupation as a well-digger suggests possible exposure to contaminated water sources harboring *Aeromonas jandaei*. The rapid and severe disease progression observed in our case was attributed to the organism's virulence factors and its intrinsic resistance to a wide range of antibiotics, including ampicillin, cefazolin, and imipenem.<sup>12</sup> *Aeromonas* species are known to produce various virulence factors such as hemolysins, cytotoxins, enterotoxins, proteases (like AspA and AhpB), lipases (Pla and Plc, Sat), DNAses, adhesins (type IV pili, polar flagella), capsule, and T3SS.<sup>3</sup> Hemolysins and proteases likely contributed to the rapid disease progression observed in our patient. Poor prognostic indicators include shock, admission to the intensive care unit, and the need for mechanical ventilation.<sup>13</sup>

The overuse of antibiotics has accelerated AMR development in various bacterial pathogens, leading to treatment complexities, increased mortality rates, and prolonged hospital stays. Horizontal gene transfer is a common mechanism of AMR acquisition in *Aeromonas*, as demonstrated by the ability of environmental isolates to acquire and transfer resistance genes.<sup>14</sup> In our case, *Aeromonas jandaei* exhibited resistance to beta-lactams and carbapenems, which are frequently used empirical antibiotics for severe pneumonia.<sup>8</sup> Recommended antimicrobial therapies for *Aeromonas pneumonia* typically involve third or fourth-generation cephalosporins or quinolones,<sup>10</sup> the emergence of multi-drug resistant *Aeromonas jandaei*, underlines the importance of starting appropriate antibiotics earlier in treating such infection.

## Conclusions

This case emphasizes the importance of clinical awareness regarding *Aeromonas* infections in patients presenting with rapidly progressing skin, soft tissue, gastrointestinal, or respiratory infections, particularly those with exposure to freshwater environments. Early recognition, appropriate antibiotic administration, and comprehensive supportive care are crucial for achieving favorable outcomes.

## References

1. Carnahan A, Fanning GR, Joseph SW. *Aeromonas jandaei* (formerly genospecies DNA group 9 *A. sobria*), a new sucrose-negative species isolated from clinical specimens. *J Clin Microbiol.* 1991;29:560-4.
2. Colwell RR, Macdonell MT, De Ley J. Proposal to recognize the family Aeromonadaceae fam. nov. *International Journal of Systematic Bacteriology.* 1986;36:473-7.
3. Bhowmick UD, Bhattacharjee S. Bacteriological, clinical and virulence aspects of *Aeromonas*-associated diseases in humans. *Polish Journal of Microbiology.* 2018;67:137-50.
4. Ender PT, Dolan MJ, Dolan D, et al. Near-drowning-associated *Aeromonas pneumonia*. *The Journal of Emergency Medicine.* 1996;14:737-41.
5. Sadique A, Neogi SB, Bashar T, et al. Dynamics, diversity, and virulence of *Aeromonas* spp. in homestead pond water in coastal Bangladesh. *Front Public Health.* 2021;9:692166.
6. Chang YC, Shih DY, Wang JY, Yang SS. Molecular characterization of class 1 integrons and antimicrobial resistance in *Aeromonas* strains from foodborne outbreak-suspect samples and environmental sources in Taiwan. *Diagnostic Microbiology and Infectious Disease.* 2007;59:191-7.
7. Metlay JP, Waterer GW, Long AC, et al. Diagnosis and treatment of adults with community-acquired pneumonia. An official clinical practice guideline of the American Thoracic Society and Infectious Diseases Society of America. *Am J Respir Crit Care Med.* 2019;200:e45-67.
8. Sharma B, Singh V. Indian pneumonia guidelines. *Lung India.* 2012;29:307.
9. Slutsky AS, Marco Ranieri V. Mechanical ventilation: lessons from the ARDSNet trial. *Respir Res.* 2000;1:2.
10. Patil SM, Hilker ED. *Aeromonas hydrophila* community-acquired bacterial pneumonia with septic shock in a chronic lymphocytic leukemia patient due to absolute neutropenia and lymphopenia. *Cureus.* 2022;14:23345.
11. Igbinsosa IH, Igumbor EU, Aghdasi F, et al. Emerging *Aeromonas* species infections and their significance in public health. *The Scientific World Journal.* 2012;2012:1-13.
12. Mohan B, Sethuraman N, Verma R, Taneja N. Speciation, clinical profile & antibiotic resistance in *Aeromonas* species isolated from cholera-like illnesses in a tertiary care hospital in north India. *Indian J Med Res.* 2017;146:53.
13. Nagata K, Takeshima Y, Tomii K, Imai Y. Fulminant fatal bacteremic pneumonia due to *Aeromonas hydrophila* in a non-immunocompromised woman. *Intern Med.* 2011;50:63-5.
14. Neil B, Cheney GL, Rosenzweig JA, et al. Antimicrobial resistance in *Aeromonas* and new therapies targeting quorum sensing. *Appl Microbiol Biotechnol.* 2024;108:205.