

Solitary fibrous tumor – a rare tumor of the pleura

Yash Kedia,¹ Nitesh Gupta,² Pranav Ish,¹ Rohit Kumar²¹

¹Department of Pulmonary and Critical Care Medicine, VMMC and Safdarjung Hospital, New Delhi; ²Department of Pulmonary Medicine, VMMC & Safdarjung Hospital, New Delhi, India

Abstract

Solid lesions in the pleura could be benign, malignant, or borderline processes, the most common lesion being pleural thickening. Among pleural tumors, malignant lesions are more common as compared to benign lesions. Solitary fibrous tumors of the pleura are rare tumors of the pleura, originating from the mesenchymal tissue, which can have malignant transformation on some occa-

sions. It is difficult to differentiate the pleural tumors in radiology, and histopathology is required to make a definitive diagnosis. Usually requiring surgery, few cases can have recurrence despite complete resection.

Introduction

Tumors of the pleura are classified as mesothelial tumors, mesenchymal tumors, and lymphoproliferative disorders, as per the World Health Organization (WHO) 2015 classification. Malignant tumors, particularly metastasis, are more common than benign tumors of the pleura. Metastasis to pleura can occur due to hematogenous spread, lymphatic spread, or direct extension of a lung tumor, and is usually associated with malignant pleural effusion. The most common primary tumor of the pleura is malignant mesothelioma. Mesenchymal tumors of the pleura are rare and include angiosarcomas, synovial sarcomas, solitary fibrous tumors, desmoid type fibromatosis, and desmoplastic round cell tumors.¹

Case Report

A 61-year-old non-smoker woman was admitted with a 2-week history of intermittent, right-sided chest pain. She denied any dyspnea, cough, hemoptysis, palpitations, sweating, or syncope episodes. There was no history of trauma, and past medical and family history was unremarkable. On examination, the patient was vitally stable, with a room air oxygen saturation of 96%. On thoracic examination, the right hemithorax had fullness, and reduced movement. On palpation of the chest, movements and tactile vocal fremitus were reduced on the right side in the interscapular and infrascapular areas. On percussion, a dull note was appreciated and on auscultation, breath sounds were reduced in the corresponding areas. The remainder of her systemic examination was unremarkable. The laboratory reports were essentially normal. A chest radiograph showed well-defined opacity in the right hemithorax with blunting of the right costophrenic angle (Figure 1A). Ultrasonography documented right-sided pleural effusion and a solid mass-like structure in the pleura (Figure 1B). The patient further underwent a Fluorodeoxyglucose (FDG) Positron Emission Tomography Computerized Tomography (PET CT) scan of the whole body (Figure 2), which revealed lobulated, mildly FDG avid pleural base 10.2x8.2x12.3 cm mass lesion (Standardized Uptake Value, SUV, max 4.1) with areas of internal necrosis in right hemithorax, causing a passive collapse of the right lung, with right-sided moderate pleural effusion. Ultrasound-guided pleural fluid aspiration was hemorrhagic, and cytology suggested atypical squamous epithelial cells and inflammatory infiltrates. The squamous epithelial cells had a high N/C ratio and moderate cytoplasm, favoring malignancy. The patient was referred to cardiothoracic surgery for surgical excision of the mass. The patient was subjected to a Video-Assisted

Correspondence: Yash Kedia, Department of Pulmonary Medicine, VMMC & Safdarjung Hospital, New Delhi 110029, India. Tel. +91.9619492234.

E-mail: yskedia@gmail.com.

Key words: pleura, tumor, solitary fibrous tumor.

Contributions: YK, NG, PI, RK, RK, NG, and TT were involved in the literature search, planning, conducting, and writing the original draft of the manuscript, literature search, and editing of the study; PI is corresponding author and guarantor for all. All the authors have read and approved the final version of the manuscript and agreed to be held accountable for all aspects of the work.

Conflict of interest: the authors declare no potential conflict of interest.

Funding: none.

Ethics approval and consent to participate: not applicable.

Informed consent: the patient gave her written consent to use her personal data for the publication of this case report and any accompanying images.

Availability of data and materials: all data generated or analyzed during this study are included in this published article.

Received: 5 July 2024.

Accepted: 1 August 2024.

Early Access: 8 August 2024.

This work is licensed under a Creative Commons Attribution-NonCommercial 4.0 International License (CC BY-NC 4.0).

©Copyright: the Author(s), 2024

Licensee PAGEPress, Italy

Chest Disease Reports 2024; 12:12786

doi:10.4081/cdr.2024.12786

Publisher's note: all claims expressed in this article are solely those of the authors and do not necessarily represent those of their affiliated organizations, or those of the publisher, the editors and the reviewers. Any product that may be evaluated in this article or claim that may be made by its manufacturer is not guaranteed or endorsed by the publisher.

Thoracoscopic Surgery (VATS), through a port via the 5th intercostal space. Active bleeding was visualized from the tumor, and there was no evidence of any other pleural deposits. In view of active bleeding, posterolateral thoracotomy was done in the 5th intercostal space. The tumor was removed *en bloc*, and thoracotomy was closed after inserting an intercostal drainage tube in the right pleural space. Histopathology of the tumor was suggestive of an encapsulated spindle cell tumor with mild to moderate cellularity. The stroma showed dense collagen bundles along with occasional lymphocytes. Few scattered mitosis was seen, and no nuclear atypia or necrosis was identified. The tumor cells were positive for STAT6, focally positive for CD34, and negative for SMA, desmin, and SOX10, thus clinching a diagnosis of a solitary fibrous tumor of the pleura. Ki67 index was approximately 3%. Post-surgical chest X-ray revealed a completely expanded lung (Figure 3).

Discussion

Solitary Fibrous Tumors of the Pleura (SFTP) are slow-growing tumors that usually occur in the 45 to 60 years age group. They represent less than 5% of primary pleural neoplasms, and the reported incidence is 2.8 per 1,00,000 people. Other terminologies used to describe SFTP include localized mesothelioma, hemangiopericytoma, localized benign fibroma, and localized fibrous tumor. Most of these tumors are benign, but 20% can be malignant. A larger size of the tumor, the presence of associated pleural effusion, and a high Ki67 proliferation index are associated with malignant histology. SFTP arises from the visceral pleura in 80% of the cases and can grow into large masses (often more than 10 cm) before becoming symptomatic. These tumors may be associated with hypertrophic osteoarthropathy (Pierre-Marie-Bamberger syndrome) due to the production of ectopic growth hormone-like substance and hypo-

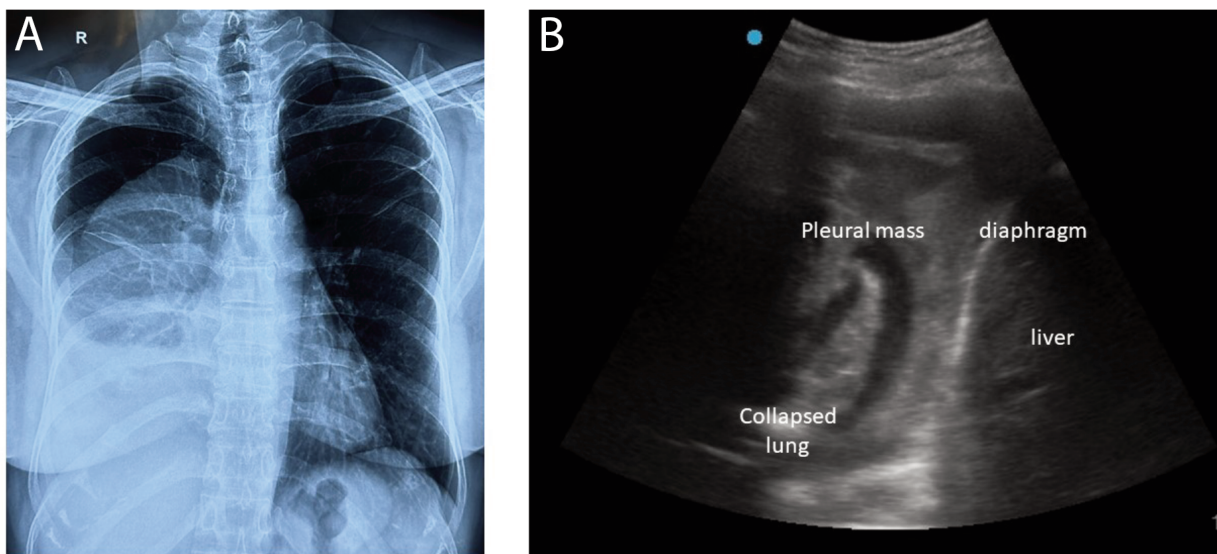


Figure 1. A) Chest X-ray on presentation s/o a large lobulated mass-like lesion in the right hemithorax with blunting of the right costophrenic angle. B) Chest ultrasonography showing a mass lesion in the pleura.

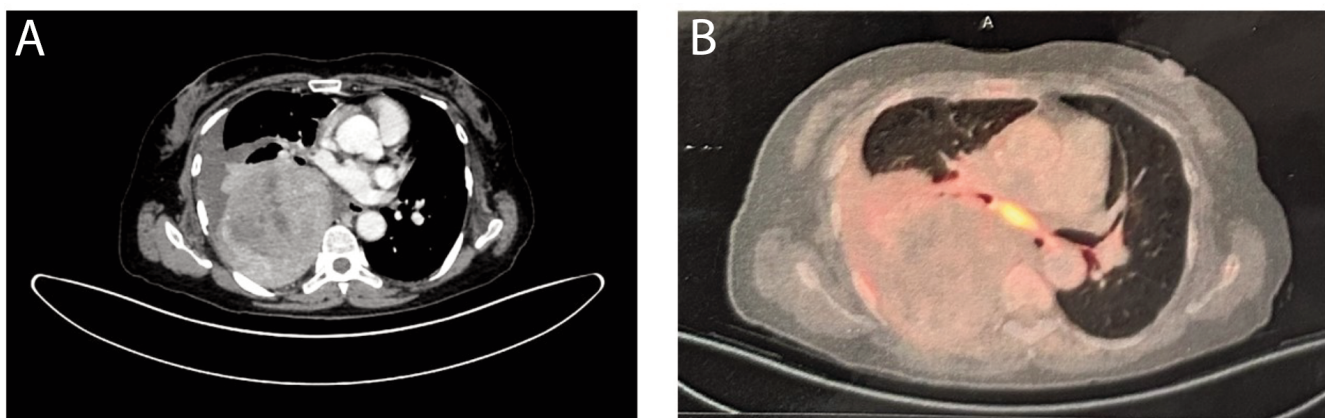


Figure 2. Positron Emission Tomography Computerized Tomography (PET CT) shows a mildly Fluorodeoxyglucose (FDG)-avid (Standardized Uptake Value, SUV, max 4.1) heterogeneously enhancing pleural-based soft tissue mass lesion with areas of internal necrosis, measuring 10.2x8.2x12.3 cm.

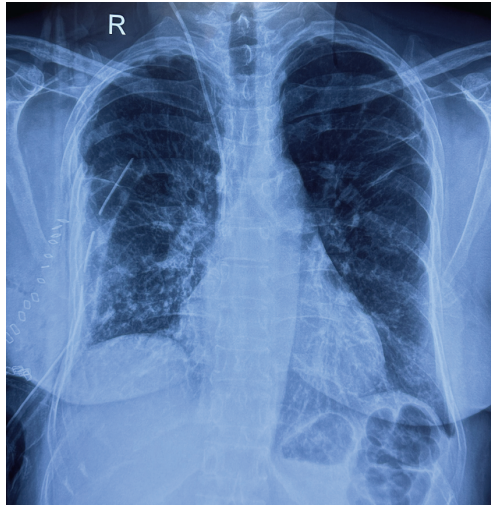


Figure 3. Chest X-ray post-surgery showed a completely expanded lung with an intercostal drainage tube *in situ* and thoracotomy staples.

glycemia (Doegge–Potter syndrome) due to the production of insulin-like growth factor II. Post-surgery, symptoms due to both these syndromes are relieved almost immediately.^{2,3} On chest X-ray, SFTP appears like a solid, peripheral, sharply defined, homogenous mass, having a stalk and may be mobile with respiration. There may be an associated pleural effusion. CT Chest shows a round, well-circumscribed mass, which may show areas of necrosis, hemorrhage, and cystic changes, and may show contrast enhancement. The contrast enhancement is frequently non-homogenous, due to areas of intermixed high vascularity and foci of myxoid or cystic degeneration. Areas of calcification may be seen rarely within the tumor.⁴ MRI may help to delineate the boundaries of the tumor and may show necrosis, hemorrhage, or cystic changes if present. When a central focus of heterogeneity and variable contrast enhancement is identified in a solitary fibrous tumor on CT or Magnetic Resonance Imaging (MRI), higher-risk tumors should be considered. PET has shown excellent accuracy in differentiating benign from malignant fibrous pleural disease. Studies have shown that benign solitary fibrous tumors typically show a low level of FDG uptake (SUV <2.5). In addition, preoperative FDG PET/CT can be used in surgical planning and identifying distant metastasis.⁵ Grossly, these tumors appear as firm, encapsulated, and vascular tumors. Histopathology is crucial to confirm the diagnosis, and typical histopathology shows hypocellularity with dense collagenous stroma and irregularly arranged fascicles that consist of spindle cells. This arrangement is typically referred to as a “patternless pattern”. Immunohistochemistry shows positivity for CD34, BCL-2, vimentin, and CD99.^{2,6} Surgical resection is the treatment of choice for SFTP. Even after complete surgical resection, more than 25% of cases can show recurrence. There is a good 5-year survival after surgery, but malignant histology shows higher recurrence and poorer survival.

Conclusions

Solitary fibrous tumors of the pleura are rare neoplasms, which may recur even after complete surgical resection. CT Scan and MRI of the chest may be non-specific and histopathology is essential to make a diagnosis.

References

1. Sauter JL, Dacic S, Galateau-Salle F, et al. The 2021 WHO classification of tumors of the pleura: advances since the 2015 classification. *J Thorac Oncol.* 2022;17:608-22.
2. Abodunrin FO, Killeen RB. Pleural solitary fibrous tumors. 2024. Available from: <https://www.ncbi.nlm.nih.gov/books/NBK585038/>
3. Fatimi SH, Inam H, Chagan FK, Choudry UK. Solitary fibrous pleural tumor. A rare and challenging case. *International Journal of Surgery Case Reports.* 2020;66:346-9.
4. Desimpel J, Vanhoenacker FM, Carp L, Snoeckx A. Tumor and tumorlike conditions of the pleura and juxtapleural region: review of imaging findings. *Insights into Imaging.* 2021;12:97.
5. Sureka B, Thukral BB, Mittal MK, et al. Radiological review of pleural tumors. *Indian J Radiol Imaging.* 2013;23:313-20.
6. Robinson LA. Solitary fibrous tumor of the pleura. *Cancer Control.* 2006;13:264-9.
7. Mercer RM, Wigston C, Banka R, et al. Management of solitary fibrous tumours of the pleura: a systematic review and meta-analysis. *ERJ Open Research.* 2020;6:00055-2020.