

A 70-year-old man with a drooping eyelid and distended chest veins

Rahul Tyagi,¹ Kislay Kishore,¹ Siddhartha Chakraborty,¹ Ritwik Chakrabarti,² Manu Chopra,¹ I. M. Pandey¹

¹Department of Respiratory Medicine, Army Institute of Cardio-Thoracic Sciences (AICTS)/Armed Forces Medical College (AFMC), Pune; ²Department of Radiodiagnosis and Interventional Radiology, Army Institute of Cardio-Thoracic Sciences (AICTS)/Armed Forces Medical College (AFMC), Pune, India

Abstract

Horner's Syndrome and central venous obstruction are usually seen in patients with superior sulcus tumour, and their presence, especially in elderly patients, is alarming. Benign causes of

Horner's Syndrome and central venous obstruction are rare but well-documented in the literature. A combination of both occurring due to clavicular trauma is extremely rare. We report a case of an elderly male with clavicular trauma who presented with Horner's Syndrome and central venous obstruction. He was managed conservatively and had a complete resolution of symptoms. This case highlights that even "red flag" clinical signs may represent relatively innocuous etiology, and thorough evaluation is essential before reaching a diagnosis.

Correspondence: Rahul Tyagi, Department of Respiratory Medicine, Army Institute of Cardio-Thoracic Sciences (AICTS)/Armed Forces Medical College (AFMC), Pune, India.
Tel. 7798575844. E-mail: rahultyagi4960@gmail.com

Key words: case report, drooping eyelid, distended chest veins, Horner Syndrome.

Contributions: RT, manuscript preparation and editing, patient management, guarantor; KK, case presentation, manuscript preparation and editing, patient management; SC, manuscript preparation and editing, patient management, collection of relevant data; RC, manuscript preparation and editing, patient management; MC, manuscript preparation and editing, patient management; IMP, manuscript preparation and editing, patient management. All the authors have read and approved the final version of the manuscript and agreed to be held accountable for all aspects of the work.

Conflict of interest: the authors declare no potential conflict of interest.

Funding: none.

Ethics approval and consent to participate: not applicable.

Patient's consent for publication: the patient gave his written consent to use his personal data for the publication of this case report and any accompanying images.

Availability of data and materials: all data generated or analyzed during this study are included in this published article.

Received: 6 May 2024.

Accepted: 18 June 2024.

Early view: 28 June 2024.

This work is licensed under a Creative Commons Attribution-NonCommercial 4.0 International License (CC BY-NC 4.0).

©Copyright: the Author(s), 2024

Licensee PAGEPress, Italy

Chest Disease Reports 2024; 12:12638

doi:10.4081/cdr.2024.12638

Publisher's note: all claims expressed in this article are solely those of the authors and do not necessarily represent those of their affiliated organizations, or those of the publisher, the editors and the reviewers. Any product that may be evaluated in this article or claim that may be made by its manufacturer is not guaranteed or endorsed by the publisher.

Case Report

A 70-year-old male presented with complaints of breathlessness on exertion along with a dry cough and swelling of the left upper limb for five days duration. There was no history of fever, hemoptysis, or hoarseness of voice. On direct questioning, he also noted reduced sweating over the left side of his face. He was a non-smoker, and there was no past history of tuberculosis. Medical history was notable for hypertension, Chronic Kidney Disease (CKD), and dilated cardiomyopathy with complete heart block for which the patient was on a permanent pacemaker. Upon examination, the patient was alert and responding to commands. His vitals were pulse rate of 70/min, BP of 110/68 mm Hg, respiratory rate of 20/min, and SpO₂ of 94% on room air. He was found to have left upper limb swelling, dilated veins over his left infraclavicular region, swelling over the medial aspect of his left clavicle, and drooping of his left eyelid (Figure 1). He had undergone cataract surgery and was noticed to have irregular pupils on his left side. A bilateral polyphonic wheeze was heard in all lung fields, along with coarse basal crackles on auscultation. The rest of the neurological and cardiovascular examination was normal. When asked about the swelling in the region of the clavicle, he gave a history of trauma to the upper part of the left chest around ten days prior, when he was hit by a bull. Following the accident, he developed pain and swelling over the medial part of his collarbone. The pain had reduced after the use of some over-the-counter pain relief medications, but the swelling had persisted. Investigations revealed 11 mg/dL hemoglobin and a normal total and differential leucocyte count. Urea was 62 mg/dL, and creatinine levels were 2.3 mg/dL. His 2-D echocardiography showed an ejection fraction of 15% with global hypokinesia. Brain Natriuretic Peptide (BNP) levels were normal. Ultrasound and Doppler of left clavicular swelling showed a hetero-echoic lesion with foci of calcification in the left lower cervical region with the absence of any vascularity, which was causing a reduction in the diameter of the left subclavian vein (Figure 2). There was no thrombus in the left neck veins. Non-Contrast Computed Tomography (NCCT) of the neck and chest showed a fracture at the medial end of the left clavicle with early callus formation (Figure 2) and anterior subluxation at the left sternoclavicular joint. A contrast study could not be performed because of underlying CKD.

Based on the clinical and radiological evaluation, the patient was diagnosed as having a fracture of the medial end of the clavicle, causing Horner's Syndrome and central venous obstruction. The patient was managed symptomatically with the change of an intravenous cannula to the right hand and the use of diuretics, bronchodilators, and other supportive measures. As his breathlessness improved, the patient was discharged and asked to review in our patient department for regular follow-up. After eight weeks, there was significant resolution of ptosis along with complete resolution of dilated veins over the left shoulder region (Figure 3).

Discussion

Horner's Syndrome and central venous obstruction are commonly seen in malignant disorders. Although rare, benign causes of both Horner's Syndrome and central venous obstruction have also been reported.¹⁻³ However, a combination of Horner's Syndrome and central venous obstruction due to benign causes is extremely rare. To our knowledge, this is the first report of fracture of the medial end of the clavicle with anterior subluxation of the sterno-clavicular joint presenting features of both Horner's Syndrome and venous obstruction.

Horner syndrome, named after the Swiss ophthalmologist Johann Friedrich Horner, is a rare condition where the patient presents with partial ptosis (drooping of the upper eyelid), miosis (constriction of the pupil), and anhidrosis (absence of sweating).² Our patient had ptosis and anhidrosis, but miosis could not be demonstrated due to the operative status of the eye. Venous obstruction of central veins is a red flag sign and usually points to an underlying malignancy. However, benign causes such as insertion of indwelling catheters, radiation fibrosis, infection, retrosternal thyroid, aortic aneurysm, and sarcoidosis causing central

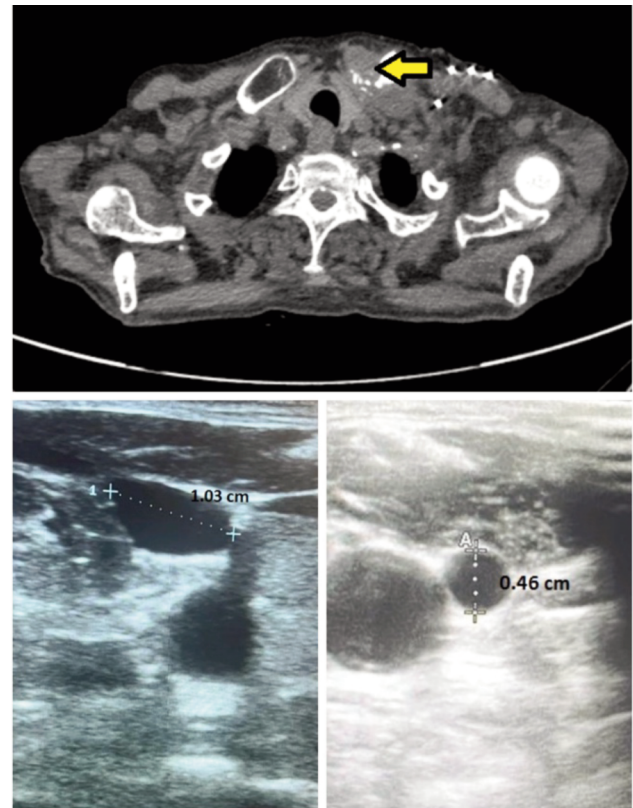


Figure 2. Yellow arrow showing callus formation over medial end of clavicle on high resolution chest tomography. Ultrasound of the neck showed a compressed left subclavian vein (measuring 0.46 cm) compared to the normal-sized right subclavian vein (1.03 cm).

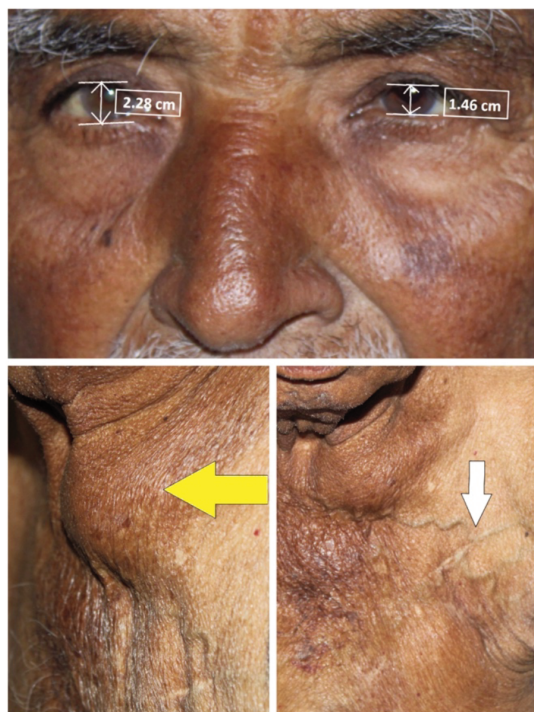


Figure 1. The image shows the ptosis of the left eye of the patient. Yellow arrow showing swelling over medial end of the clavicle and a white arrow showing dilated veins over the left shoulder.

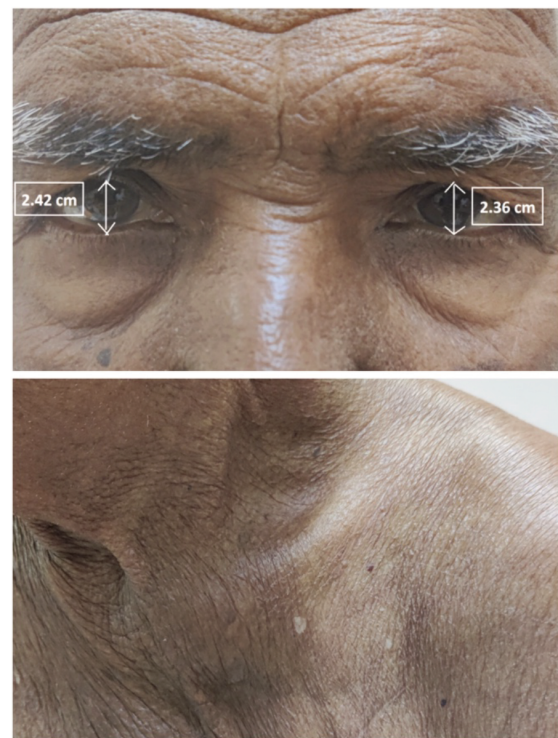

Figure 3. The image shows the complete resolution of ptosis and dilated veins after eight weeks.

venous obstruction have also been reported.⁴ Clinical presentation of venous obstruction depends on the level of obstruction, and some common presentations include facial edema, nonpulsatile distended neck veins, distended chest veins, breathlessness and cough, arm edema, syncope, and headache.⁴ Rib fractures and cervical trauma have been known to cause Horner's Syndrome, but there are only a few cases reported of fracture of the clavicle causing Horner's Syndrome.¹ The fracture site is close to the thoracic outlet, and hence the displaced bony fragment, along with callus formation or hematoma, can cause compression of second-order neurons, leading to Horner's Syndrome. Simultaneously, compression of the subclavian vein due to the callus formation led to the patient presenting with features of venous obstruction. In our case, initially, the inflammation and callus caused the compression of the sympathetic nerve and subclavian vein. As the callus organized and the inflammation reduced, the patient had recovery from the compressive symptoms. Lin *et al.* in their review of the literature, found that all cases of clavicular fracture resulting in Horner's Syndrome were unimproved at follow-up, except for their case.¹ This shows that recovery with conservative management in such cases is rare but possible. In our case, operative management was not considered due to the age and significant comorbidities of the patient, which made him a high-risk candidate for surgery. Complete recovery in our patient shows that conservative management does have a role, especially in high-risk surgical candidates.

Conclusions

This case shows that Horner's Syndrome and central venous obstruction can present together even in benign aetiologies. Even the most alarming clinical signs may have a benign cause, which is easily demonstrable by detailed evaluation. Conservative management should be considered, especially in nonlife or limb-threatening injuries for patients who are high-risk surgical candidates.

References

1. Lin CY, Chang HW, Chang YH, et al. Isolated middle-third clavicle fracture causing Horner's Syndrome: a case report and literature review. *Front Surg.* 2021;8:640900.
2. Khan Z, Bollu PC. Horner Syndrome. 2023. Available from: <http://www.ncbi.nlm.nih.gov/books/NBK500000/>.
3. Mawatari T, Watanabe A, Harada R, et al. Traumatic dislocated clavicle fracture with the oppression of superior vena cava. *Asian Cardiovasc Thorac Ann.* 2006;14:85.
4. Collin G, Jones RG, Willis AP. Central venous obstruction in the thorax. *Clin Radiol.* 2015;70:654-60.