

A case report of an intra-pleural foreign body successfully retrieved by semi-rigid thoracoscopy and systematic review of worldwide literature

Sanchit Mohan, Rohit Kumar, Manu Madan, Pranav Ish, Rajnish Kaushik, Nitesh Gupta

Department of Pulmonary Medicine, Critical Care and Sleep, Vardhman Mahavir Medical College and Safdarjung Hospital, New Delhi, India

Abstract

Intra-pleural foreign bodies occur due to thoracic trauma or iatrogenic. Extraction of an intra-pleural foreign body is done either by thoracotomy or Video-Assisted Thoracoscopic Surgery (VATS). A 58-year-old woman presented with a right pleural effusion. Ultrasonography (USG)-guided right pleural fluid aspiration

complicated as the needle broke down in the pleural cavity. Computed Tomography (CT) of the thorax documented the needle in the muscular plain between intercostal muscles and the pointing edge in the pleural cavity. A surgical exploration of the muscular plane to retrieve the needle was unsuccessful. The needle was successfully extracted by semi-rigid thoracoscopy under local anesthesia without any complications.

Correspondence: Nitesh Gupta, Department of Pulmonary Medicine, Critical Care and Sleep, Vardhman Mahavir Medical College & Safdarjung Hospital, New Delhi 110027, India. Tel. 9873096364. E-mail: niteshgupta2107@gmail.com

Key words: foreign bodies, pleura, thoracic diseases, case studies, systematic reviews, thoracoscopy.

Contributions: SM, RK, MM, PI, RJK, and NG were involved in the conceptualization, literature search, writing of the original draft of the manuscript, literature search, planning, conduct, and editing; NG was involved in review and editing, and will act as guarantor on behalf of all authors. All the authors have read and approved the final version of the manuscript and agreed to be held accountable for all aspects of the work.

Conflict of interest: the authors declare no potential conflict of interest.

Funding: none.

Ethics approval and consent to participate: not applicable.

Patient's consent for publication: written and informed consent for publication was taken from the patient's kin.

Availability of data and materials: all data generated or analyzed during this study are included in this published article.

Received: 23 April 2024.

Accepted: 6 May 2024.

Early view: 8 May 2024.

This work is licensed under a Creative Commons Attribution-NonCommercial 4.0 International License (CC BY-NC 4.0).

©Copyright: the Author(s), 2024

Licensee PAGEPress, Italy

Chest Disease Reports 2024; 12:12599

doi:10.4081/cdr.2024.12599

Publisher's note: all claims expressed in this article are solely those of the authors and do not necessarily represent those of their affiliated organizations, or those of the publisher, the editors and the reviewers. Any product that may be evaluated in this article or claim that may be made by its manufacturer is not guaranteed or endorsed by the publisher.

Introduction

Foreign bodies lodged within the tracheobronchial tree and gastrointestinal tract are relatively common, contrasting with intra-pleural foreign bodies, which typically result from trauma or iatrogenic causes.¹ Needle thoracentesis serves as a standard diagnostic procedure for identifying the underlying cause of pleural effusion.² However, despite the safety and simplicity of the procedure, complications such as needle breakdown within the pleural cavity can occur. Extraction of intra-pleural foreign bodies traditionally requires thoracotomy or Video-Assisted Thoracoscopic Surgery (VATS).³ We present a case of successful intra-pleural foreign body retrieval using semi-rigid thoracoscopy under local anesthesia. Additionally, we systematically review the existing literature on the efficacy of semi-rigid thoracoscopy for extracting intra-pleural foreign bodies.

Case Report

This case report details the management of a 58-year-old woman diagnosed with diabetes mellitus, hypertension, and chronic kidney disease, who presented with moderate right pleural effusion. An Ultrasonography (USG)-guided attempt to aspirate the pleural fluid using a 22G needle resulted in the patient experiencing syncope, causing the needle to break in the pleural cavity. Subsequent Computed Tomography (CT) thorax imaging revealed the needle lodged in the muscular plane between intercostal muscles, with one end penetrating into the pleural cavity (Figure 1a-c). Despite surgical exploration of the area, the needle remained unretrieved (Figure 1d), prompting referral to our center for further intervention.

On presentation, the patient had stable vital signs but had undergone prior surgical exploration, evidenced by multiple sutures in her lateral chest wall. Despite efforts to visualize the needle using USG, it remained elusive. A trocar was inserted, and under local anesthesia with 4% lignocaine, a semi-rigid thoracoscope (Model LTF 160; Olympus; Tokyo, Japan) was introduced through the trocar.

The semi-rigid thoracoscope facilitated visualization of the needle embedded in the lung tissue (Figure 2a), with a portion protruding into the pleural cavity. With fenestrated forceps, the needle was grasped and successfully (Figure 2b) removed under direct vision (Figure 2c). The embedded length of the needle in the lung was approximately 3.5 cm (Figure 2d). Post-procedure, a 28-mm

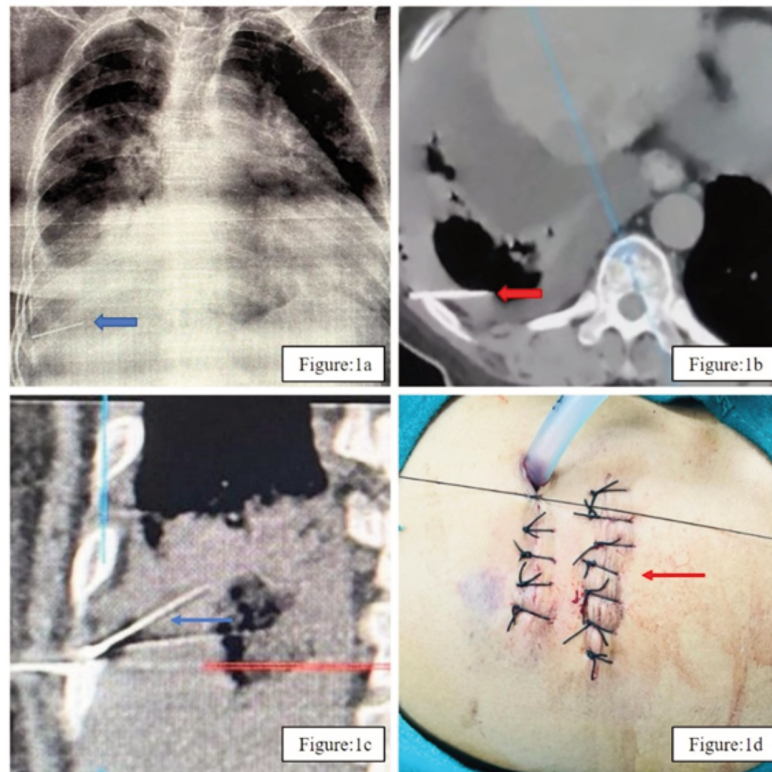


Figure 1. **a**) A foreign body in chest radiography (blue thick arrow); **b**) shows an axial Computed Tomography (CT) of the thorax image with the needle in the pleural cavity and head in muscular plain (thick red arrow); **c**) shows sagittal section of the CT with needle embedded in lung with head in the muscular plain (thin blue arrow); **d**) shows scar and sutures post-surgical exploration of muscular plain (thin red arrow).

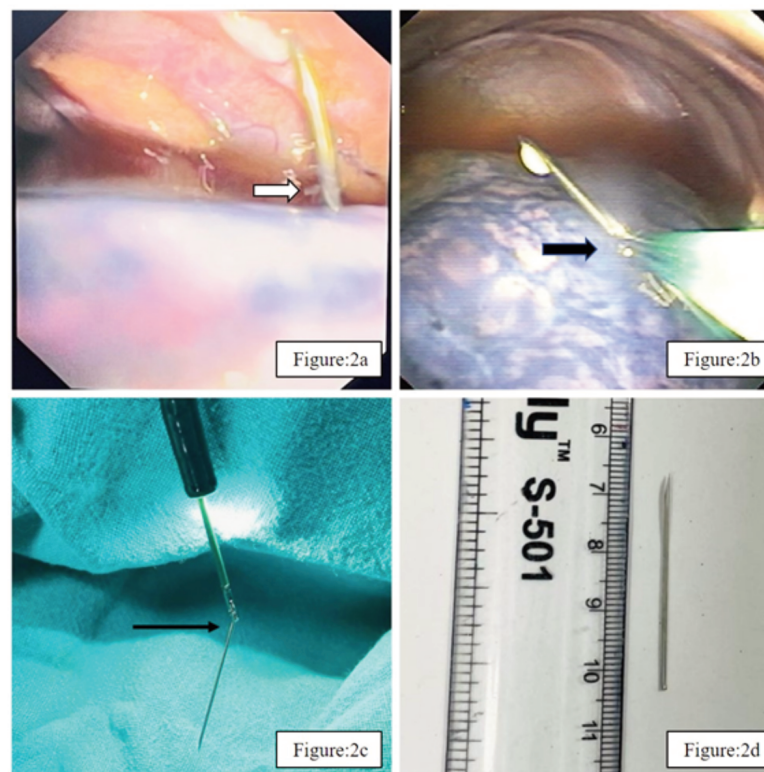


Figure 2. **a**) Shows the needle embedded in the lung (white thick arrow); **b**) shows the needle grasped by biopsy forceps (thick black arrow); **c**) shows the successful removal of the needle en bloc with a semi-rigid thoracoscope (thin black arrow); **d**) shows needle length of approximately 3.5 cm.

F thoracostomy tube was placed in the pleural cavity and removed after 24 hours, with no complications reported.

Discussion

Thoracentesis is a commonly performed low-risk procedure in both inpatient and outpatient settings for diagnosing pleural effusion. Complications of thoracentesis may include pneumothorax, puncture site bleeding, hemothorax, chest wall hematoma, and re-expansion pulmonary edema.⁴ Needle breakdown inside the pleural cavity during thoracentesis has been rarely reported in the literature.⁵

Semi-rigid thoracoscopy serves as a diagnostic tool for evaluating undiagnosed pleural effusion, and its therapeutic role in adhesiolysis and pleurodesis is well-established.⁶

Foreign bodies in the thoracic cavity can be removed either by thoracotomy or VATS. Weissberg *et al.* demonstrated retrieval of foreign bodies by thoracotomy, rigid thoracoscopy, VATS, and simple incision in 21 patients.⁷ The index case highlights the successful use of a semi-rigid thoracoscopy in the removal of an intrapleural sharp foreign body.

To gather additional insights, we conducted a systematic review using the mesh terms “pleura,” “foreign bodies,” “thoracic disease,” “case studies,” “systematic reviews,” “thoracoscopy,” and “medical thoracoscopy” on PubMed and Google Scholar databases. From the 192 articles initially identified, 8 case reports were included in the final evaluation after applying exclusion criteria (Figure 3). The retrieved information included reference/journal name, year of publication and country, patient’s age and sex,

type and cause of foreign body, attempts at local extraction, instrument used, use of USG for screening or localization, type of forceps, anesthesia and sedation, procedure complications, and duration after which the patient was discharged post-procedure (Table 1). Several foreign bodies in the pleura have been described in the literature, such as pigtail catheters,⁸ pleural catheters,⁹ Self-Expanding Metallic Stent (SEMS),¹⁰ needles,⁵ sewing needles, and surgical blades.^{3,11} Most of the foreign bodies described are iatrogenic, with few resulting from trauma.² Semi-rigid thoracoscopy has shown successful retrieval of foreign bodies under local anesthesia without complications. The first successful medical thoracoscopy to remove a surgical blade was done by bronchoscope through a thoracostomy tube.¹¹

A semi-rigid thoracoscope under local anesthesia has been used successfully by Cheng WC *et al.*¹⁰ to remove SEMS from the thoracic cavity, which migrated into the thoracic cavity due to Bronco-Pleural Fistula (BPF). Gupta Re *et al.*¹² removed a broken needle successfully, and the patient was discharged after the third day. In 2023, Bajad *et al.*⁸ used a semi-rigid thoracoscopy under general anesthesia and extracted a broken pigtail catheter from the pleural cavity, and the patient was discharged after 24 hours. Tie *et al.*² used a semi-rigid thoracoscope in 2012 to retrieve a sewing needle; however, the author had to extend the incision to insert rigid bronchoscopy forceps through the side of the trocar. The procedure was complicated as the needle broke down into 3 pieces, but they could extract the parts safely. In the index case, semi-rigid thoracoscopy was used to extract the broken needle under local anesthesia with minimal sedation, and the patient could be discharged after 24 hours of the procedure with successful removal of the intercostal tube.

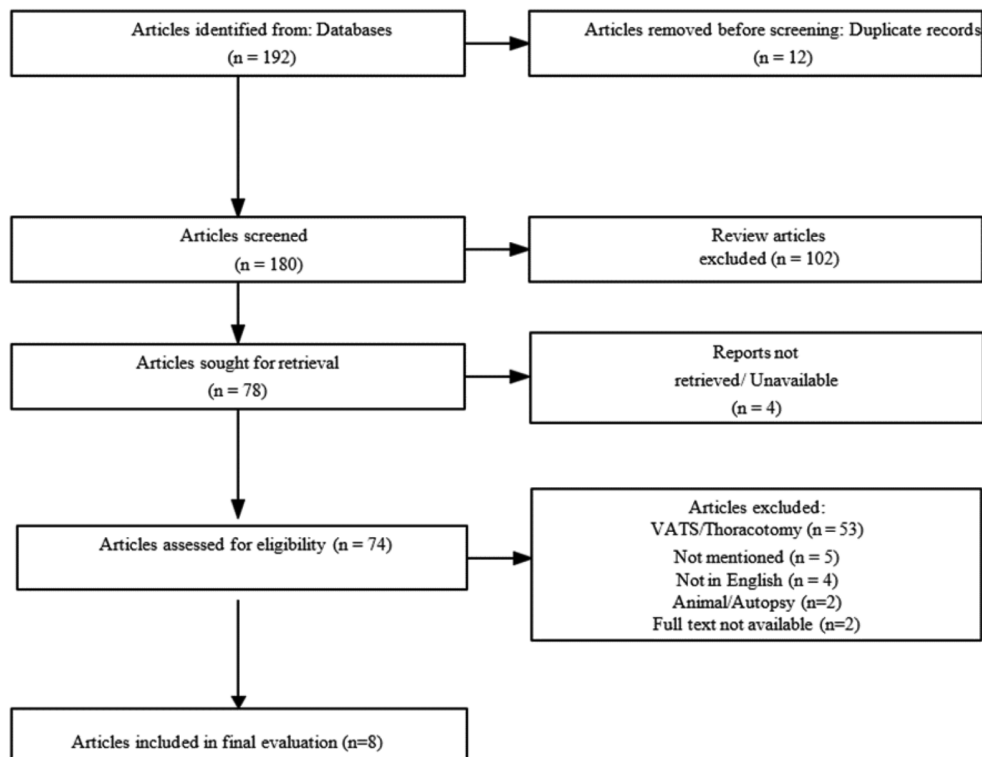


Figure 3. Flow chart.

Table 1. Published literature on intra-pleural foreign body retrieval by medical thoracoscopy.

S.No	Reference	Year/ Country	Age/Sex	Type of FB	Cause of FB	Local surgical extraction	Instrument used	US for site marking	Forceps used	Anesthesia	Sedation	Complication	Discharged
1	Present case	India	58/F	Needle	Breakage during thoracentesis	Yes, unsuccessful	Semi-rigid thoracoscope	Used	Fenestrated biopsy forceps	Local	100 meg fentanyl	None	After 24 hours
2	Bajad <i>et al.</i> ^[5] Egyptian Journal of Bronchology	India/2023	65/M	Pigtail catheter	Breakage of distal end during removal	No	7 mm semi-rigid thoracoscope	Used	Biopsy forceps	General	Propofol	None	After 24 hours
3	Sumlani <i>et al.</i> ^[9] Turkish Thoracic Journal	Rome/2022	22/F	Pleural catheter	Breakage during insertion	No	10 mm rigid thoracoscope	Used	Rigid forceps	Local	Midazolam, nalbuphine	None	After 6 days
4	Cheng <i>et al.</i> ^[6] Journal of Thoracic Disease	China/2018	66/M	Self-Expanding Metallic Stent (SEMS)	Broncho-Pleural Fistula	No	Semi-rigid thoracoscope	Used	Grasping forceps	Local	Midazolam	None	Not mentioned
5	Narasimhan <i>et al.</i> ^[7] Journal of Bronchology	India/2017	80/M	Needle	Breakage during thoracentesis	Yes, unsuccessful	10 mm rigid thoracoscope	Used	Grasping forceps	Local	Midazolam and pethidine	None	After 24 hours
6	Narasimhan <i>et al.</i> ^[5] Journal of Bronchology	India/2017	32/F	Needle	Breakage during thoracentesis	No	10 mm rigid thoracoscope	Used	Grasping forceps	Local	Midazolam and pethidine	None	After 24 hours
7	Gupta <i>et al.</i> ^[2] BMJ Case Reports	India/2014	60/M	Needle	Breakage during thoracentesis	No	Semi-rigid thoracoscope	Used	Grasping forceps	Local	Midazolam	None	3rd day
8	Tie <i>et al.</i> ^[3] Journal of Bronchology	Malaysia/2012	24/M	Sewing needle	Accidental fall on sewing needle	Yes, unsuccessful	Semi-rigid thoracoscope	Not used	Rigid bronchoscopy forceps along side of thoracoscope, another artery forceps passed through trocar	Local	Midazolam and pethidine	Needle broke into 3 pieces	After 3 days
9	Singh <i>et al.</i> ^[3] Indian Journal of Fundamental and Applied Science	India/2012	27/M	Surgical blade	Blade slipped in left pleural cavity during chest tube insertion	No	Rigid esophagoscope	Not used	Grasping forceps	General	Not mentioned	None	Same evening
10	Beg <i>et al.</i> ^[1] /Indian J of Chest Disease	India/1990	30/M	Surgical blade	Not mentioned	No/Flexible bronchoscope through intercostal tube/Not used			Grasping forceps	Not mentioned	Not mentioned	None	Not mentioned

FB, Foreign Body; US, Ultrasound.

As in the index case, surgical exploration of the site of thoracentesis has been done in literature to retrieve the needle. However, it went in vain.^{2,5} It only complicated the procedure as it further led to the displacement of the needle. Hence, surgical exploration should be avoided.

In the current era, semi-rigid thoracoscopy may be used as an initial procedure to retrieve the foreign body from the pleural cavity, but if the foreign body is complicated by adhesions, hemothorax, or if the foreign body is large, VATS or open thoracostomy should be done to extract the foreign body.¹³ CT of the thorax should be done in all cases of foreign body in the pleural cavity to ascertain that the foreign body is not involving any vascular structures or not invading the mediastinum because in those cases, VATS or open thoracostomy should be preferred without attempting semi-rigid thoracoscopy as it may complicate the procedure. USG should always be done before performing semi-rigid thoracoscopy as it may guide the path to insert the trocar and help localize the foreign body.¹⁴

This review also highlights complications of common pleural procedures like thoracentesis, intercostal drainage, and pigtail insertion. Though rarely occurring, these complications can be devastating and hence should be kept in mind. Any delay in extraction may either lead to adhesions and fibrosis or may lead to empyema, hemothorax, pericardial tamponade, diaphragmatic injury, BPF, and pericarditis requiring thoracotomy for retrieval.¹³

Conclusions

An intra-pleural foreign body is rare. It should be removed as soon as possible to prevent adhesions and fibrosis and avoid a potential thoracotomy for extraction. Semi-rigid thoracoscopy is safe, can be done under conscious sedation and local anesthesia, and may be used as an initial procedure to extract an intra-pleural foreign body. However, proper case selection and adequate training are essential for a better outcome.

References

- Ikenberry SO, Jue TL, Anderson MA, et al. Management of ingested foreign bodies and food impactions. *Gastrointest Endosc.* 2011;73:1085-91.
- Tie ST, Wong JL, Kannan SK, et al. Pleuroscopic retrieval of a sewing needle from the pleural cavity under conscious sedation by a chest physician. *J Bronchology Interv Pulmonol.* 2012;19:246-8.
- Singh SK, Kumar A, Kumar S, et al. Surgical blade: an unusual intrapleural foreign body. *Ind J Fund Appl Life Sci.* 2012;2:13-7.
- Mercaldi CJ, Lanes SF. Ultrasound guidance decreases complications and improves the cost of care among patients undergoing thoracentesis and paracentesis. *Chest.* 2013;143:532-8.
- Narasimhan RL, Sehgal IS, Dhooira S, et al. Removal of intrapleural foreign body by medical thoracoscopy: report of two cases and a systematic review of the literature. *J Bronchology Interv Pulmonol.* 2017;24:244-9.
- Maturu VN, Dhooira S, Bal A, et al. Role of medical thoracoscopy and closed-blind pleural biopsy in undiagnosed exudative pleural effusions: a single-center experience of 348 patients. *J Bronchology Interv Pulmonol.* 2015;22:121-9.
- Weissberg D, Weissberg-Kasav D. Foreign bodies in pleura and chest wall. *Ann Thorac Surg.* 2008;86:958-61.
- Bajad P, Pahuja S, Khanna A, Agarwal S. Successful removal of an iatrogenic pleural foreign body—Pigtail catheter, using a semi-rigid thoracoscope. *The Egyptian Journal of Bronchology.* 2023;17:1-4.
- Sumalani KK, Rehman U, Akhter N, Rizvi NA. Use of medical thoracoscopy for retrieval of broken intrapleural catheter. *Turk Thorac J.* 2021;22:179-81.
- Cheng WC, Wu BR, Chen CH, et al. Medical thoracoscopy removal of a self-expandable metallic stent migration into pleural cavity. *J Thorac Dis.* 2018;10:3054-8.
- Beg MH, Reyazuddin, Ansari MM. A new role of bronchofibroscope in the removal of unusual intrapleural foreign bodies. *Indian J Chest Dis Allied Sci.* 1990;32:121-3.
- Gupta R, James P, Thangakunam B, Christopher DJ. Medical thoracoscopic removal of a metal needle from the pleural space. *BMJ Case Rep.* 2014;2014:bcr2014207035.
- Lang-Lazdunski L, Mouroux J, Pons F, et al. Role of videothoracoscopy in chest trauma. *Ann Thorac Surg.* 1997;63:327-33.
- Marchetti G, Valsecchi A, Indelicati D, et al. Ultrasound-guided medical thoracoscopy in the absence of pleural effusion. *Chest.* 2015;147:1008-12.