

# Pulmonary "cannonball" metastasis from endometrial cancer: a rare case report

Marco Umberto Scaramozzino,<sup>1,2</sup> Veronica Nassisi,<sup>3</sup> Giovanni Sapone<sup>4</sup>

<sup>1</sup>Director, La Madonnina Clinic, Reggio Calabria; <sup>2</sup>Head, Thoracic Endoscopy Service, Tirrenia Hospital, Belvedere Marittimo (CS); <sup>3</sup>General Medicine Unit, San Camillo Nursing Home, Messina; <sup>4</sup>Head Nurse, Cardiology Department, Madonna della Consolazione Polyclinic, Reggio Calabria, Italy

## Abstract

Endometrial cancer is the most common gynecological neoplasm in Italy and developed countries. Pulmonary metastases, though uncommon, signify advanced disease, with «cannonball»

Correspondence: Marco Umberto Scaramozzino, Director, Outpatient Clinic of Pulmonology "La Madonnina", via San Giorgio extra 95, 89100 Reggio Calabria, Italy.  
Tel. +39 328.3074746; +39 0965-893920.  
E-mail: scaramozzinomarco91@gmail.com

Key words: cancer, cannonball, endometrial, metastasis, pulmonology.

Contributions: VN and MUS helped in the conception and design of the study; MUS did data collection; MUS did analysis and interpretation of data; MUS and VN contributed to drafting the work and revising it critically for important intellectual content; GS translated the paper to English. All authors approved the final version for publication and agreed to be accountable for all aspects of the work to ensure that questions related to the accuracy or integrity of any part of the work are appropriately investigated and resolved.

Conflict of interest: the authors declare no potential conflict of interest.

Funding: none.

Ethics approval and consent to participate: not applicable.

Patient's consent for publication: the patient gave her written consent to use her personal data for the publication of this case report and any accompanying images.

Availability of data and materials: all data generated or analyzed during this study are included in this published article.

Received: 6 March 2024.

Accepted: 19 April 2024.

Early view: 22 April 2024.

This work is licensed under a Creative Commons Attribution-NonCommercial 4.0 International License (CC BY-NC 4.0).

©Copyright: the Author(s), 2024  
Licensee PAGEPress, Italy  
Chest Disease Reports 2024; 12:12460  
doi:10.4081/cdr.2024.12460

*Publisher's note: all claims expressed in this article are solely those of the authors and do not necessarily represent those of their affiliated organizations, or those of the publisher, the editors and the reviewers. Any product that may be evaluated in this article or claim that may be made by its manufacturer is not guaranteed or endorsed by the publisher.*

metastases being a distinctive pathological finding requiring careful management. Despite advancements in bronchoscopy technology, fundamental diagnostic procedures like Bronchoalveolar Lavage (BAL), Transbronchial Lung Biopsy (TBLB), and Transbronchial Needle Aspiration (TBNA) remain essential for evaluating bronchopulmonary diseases. These techniques enhance the diagnosis and staging of oncological diseases of the genitourinary system with pulmonary involvement. Traditional bronchoscopic procedures continue to play a vital role in managing lung disorders effectively.

## Introduction

We present a case of a woman who, after undergoing hysterectomy and bilateral oophorectomy for endometrial cancer, developed respiratory symptoms, prompting diagnostic bronchoscopy at Belvedere Marittimo (CS) Internal Medicine department. Flexible bronchoscopy is pivotal for diagnosing and managing bronchopulmonary conditions, especially in patients with compromised respiratory function or extensive emphysema at risk of post-transbronchial lung biopsy pneumothorax.<sup>1</sup> Transbronchial Lung Biopsy (TBLB) remains crucial for diagnosing lung pathologies despite its declining use in advanced radiology, offering higher yields with emerging technologies. However, TBLB entails risks like pneumothorax and bleeding, requiring careful patient selection and procedural planning.<sup>2</sup> Even so, early diagnosis of metastatic endometrial tumors is crucial for improving patient prognosis. In cases like the one described, where a patient with a history of hysterectomy for benign fibroids presents with «cannonball» lung metastases, timely recognition of the metastatic nature can lead to appropriate treatment and better outcomes.<sup>3</sup>

## Case Report

A 71-year-old woman presented at the Emergency Department of Tirrenia Hospital in Belvedere Marittimo with dyspnea, hemoptysis, and tachycardia. The patient was 99% saturated in spontaneous breathing, with normal vital signs. She had no fever. Her medical history included previous uterine and ovarian removal surgery for endometrial cancer and systemic arterial hypertension. Upon admission to the Internal Medicine department, routine examinations revealed mild anemia and elevated inflammation markers. Chest X-ray indicated bilateral nodular images (Figure 1), suggestive of pulmonary metastases, prompting further investigation with a chest Computed Tomography (CT) scan and specialist pulmonary evaluation. Subsequent imaging confirmed multiple nodular formations (Figure 2A, C, D), and a mass causing complete occlusion of the middle lobar bronchus (Figure 2 B). Bronchoscopy with transbronchial biopsies (six samples) and broncho-aspirates for common germs and fungi, culture examina-

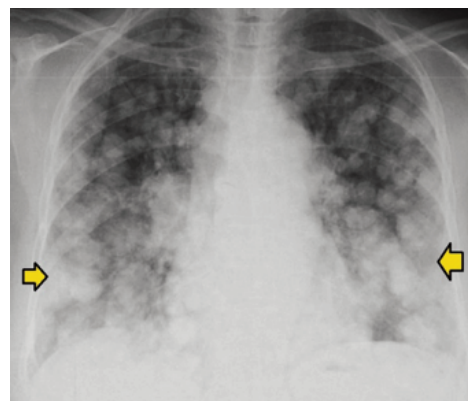tion for Koch's bacillus on broncho-aspirate, and culture examination on broncho-aspirate for atypical mycobacteria were performed. The procedure was conducted with Olympus BF 180 flexible bronchoscope with transbronchial biopsy forceps and under conscious sedation with Midazolam 4 milligrams, and there were no complications during or at the end of the endoscopic procedure. The results of the microbiological tests were negative, while the transbronchial biopsies, with the collection of 6 samples on the middle lobar bronchus, were positive for metastatic localization of endometrial adenocarcinoma (Figure 3). The patient was referred for total body PET-CT, thoracic surgical, and oncologist evaluations.

## Discussion

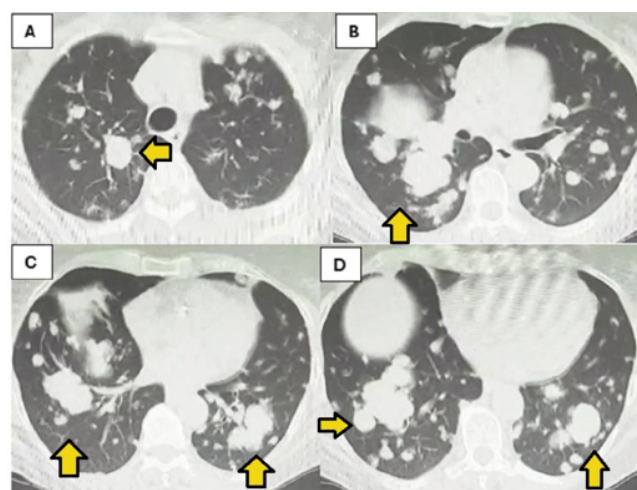
Indications for transbronchial biopsy encompass diffuse or localized infiltrates on chest x-ray, unresponsive to other interventions. Contraindications, either relative or absolute, comprise uncooperative patients, uncontrollable cough, and severe pulmonary hypertension.<sup>4</sup> Although complications such as pneumothorax and hemoptysis are infrequent, recent advancements propose blind biopsy as a viable option, particularly in immunosuppressed individuals. Nevertheless, despite innovative systems facilitating improved sample collection, the utility of Transbronchial Biopsy (TBB) remains uncertain. While TBB techniques include forceps biopsy and Endobronchial Biopsy (EBB), the latter is effective for diagnosing visible endobronchial lesions and suspected bronchogenic cancer.<sup>5</sup> Although TBB can enhance sensitivity for diagnosing conditions like pneumocystis pneumonia and tuberculosis, it may not preserve tissue integrity in all cases, necessitating alternatives like surgical biopsy.<sup>6</sup> Additionally, new techniques for lymph node sampling, such as flexible needles for endosonographic sampling and cautery-assisted transbronchial forceps biopsy, exhibit higher sensitivity in diagnosing conditions like sarcoidosis and lymphoma.<sup>7</sup> Transbronchial Lung Biopsy (TBLB) yields a diagnostic rate of 88.1% in mechanically ventilated patients, albeit associated with adverse events like pneumothorax.<sup>8</sup> Early diagnosis of metastatic endometrial tumors is pivotal for improved patient outcomes, particularly in cases presenting with «cannonball» lung metastases following hysterectomy for benign fibroids.<sup>9</sup> Pulmonary metastasis from endometrial cancer, though uncommon at initial staging, underscores the distinctive nature of certain cases' presentations and imaging correlations. Notably, lung metastasis, the most prevalent among organ metastases, has shown an increasing trend over time, with disparities observed based on demographic, socioeconomic, and tumor characteristics.<sup>10</sup>

## Conclusions

The case report highlights the importance of early diagnosis in metastatic endometrial tumors, particularly when presenting as «cannonball» lung metastases. Flexible bronchoscopy aids in diagnosing lung pathologies with low complication rates. Transbronchial biopsy remains valuable despite advancements in radiology. Factors influencing lung metastasis rates include demographics, tumor characteristics, and socioeconomic status. Early recognition of metastatic nature is crucial for appropriate treatment and improved outcomes. Pulmonary metastasis from endometrial cancer is rare, emphasizing the significance of this case's presentation.



**Figure 1.** Seventy-one-year-old woman with endometrial cancer. Chest radiograph shows innumerable pulmonary nodules and masses with «cannonball» morphology.



**Figure 2.** In panels **A**, **C**, and **D**, it is possible to see the presence of multi-nodular images also associated with endobronchial masses that take on a «cannonball» appearance of variable size (maximum diameter of 4 cm); in panel **B**, it is possible to see a mass of about 3 centimeters that occludes the middle lobar bronchus.

**Materiale inviato**  
Biopsia endobronchiale, N° : circa 6 prelievi.  
**Notizie cliniche e/o quesito diagnostico**  
Paziente con occlusione bronco lobare medio. Escludere K. Metastatico ovarico.

**DETTAGLIO MACROSCOPICO**  
Multipli minuti frammenti tissutali brunastrri.

**DIAGNOSI ISTOPATOLOGICA**  
Frammenti di mucosa bronchiale con presenza di minuti aggregati di strutture ghiandolari neoplastiche che rendono il quadro compatibile con localizzazione metastatica di Adenocarcinoma di più probabile origine endometriale ( ved. ref. istologico n° 184/2018).

T26 BRONCHI  
C3 ADENOCARCINOMA

**Figure 3.** The result of the histopathological examination of the samples taken is that the picture is compatible with the localization of metastatic adenocarcinoma of a more probable endometrial origin.

---

## References

1. Casal RF, Ost DE, Eapen GA. Flexible bronchoscopy. *Clin Chest Med.* 2013;34:341-52.
2. Shure D. Transbronchial biopsy and needle aspiration. *Chest.* 1989;95:1130-8.
3. Flavin R, Finn S, McErlean A, et al. Cannonball metastases with favourable prognosis. *Ir J Med Sci.* 2005;174:61-4.
4. Nager GT, Terry P, Marsh B, Heroy J 3rd. Transbronchial lung biopsy. *Ann Otol Rhinol Laryngol.* 1977;86:115-21.
5. James A, Carroll N. Transbronchial biopsy as a tool to evaluate small-airways disease in asthma. *Cons. Eur Respir J.* 2002;20:249-51.
6. Mondoni M, Rinaldo RF, Carlucci P, et al. Bronchoscopic sampling techniques in the era of technological bronchoscopy. *Pulmonology.* 2022;28:461-71.
7. Ghiani A, Neurohr C. Diagnostic yield, safety, and impact of transbronchial lung biopsy in mechanically ventilated, critically ill patients: a retrospective study. *BMC Pulm Med.* 2021;21:15.
8. Guo J, Cui X, Zhang X, et al. The clinical characteristics of endometrial cancer with extraperitoneal metastasis and the value of surgery in treatment. *Technol Cancer Res Treat.* 2020;19:1533033820945784.
9. Meka M, Bommireddipalli S, Killam J, et al. FDG PET Appearance of "cannonball" pulmonary metastases. *Radiol Case Rep.* 2015;4:152.
10. Mao W, Wei S, Yang H, et al. Clinicopathological study of organ metastasis in endometrial cancer. *Future Oncol.* 2020;16:525-40.