

Miliary tuberculosis in *in vitro* fertilization pregnancy: a series of three cases with a history of hypothyroidism

Apoorva Singh,¹ Urmila Singh,² Bhanu Pratap Singh,³ Mohammad Sofiyar Haroon Siddiqui⁴

¹Consultant, Midland Healthcare and Research Centre, Lucknow;

²Department of Obstetrics and Gynecology, Midland Healthcare and Research Centre, Lucknow;

³Department of Pulmonary Medicine and Critical Care, Midland Healthcare and Research Centre, Lucknow;

⁴Department of Anesthesia and Critical Care, Midland Healthcare and Research Centre, Lucknow, India

Abstract

In vitro Fertilization (IVF) pregnancy is associated with a higher risk of tuberculosis as compared to normal pregnancy. This increased risk remains unexplained. Most of the reports are based on small case series, and the risk profile is not well described. Hypothyroidism has not been described as a potential risk factor

in any series. In this case series, we elaborate on the profile of three military tuberculosis cases of IVF pregnancies, all having hypothyroidism history as the common factor, and were referred to our super-specialty center with the onset of symptoms during the late first or mid-second trimester of pregnancy. All three cases were diagnosed on X-ray chest Posterior-Anterior (PA) view, showing miliary tuberculosis and a known case of hypothyroidism. Antitubercular treatment was started. In this report, we describe the clinical course and unfavorable outcomes of these three cases.

Correspondence: Apoorva Singh, Consultant, Midland Healthcare and Research Centre, Lucknow, India.

E-mail: apoorva1105@gmail.com

Key words: *in vitro* Fertilization (IVF) pregnancy, miliary tuberculosis, hypothyroidism, antitubercular treatment.

Contributions: all the authors made a substantive intellectual contribution. All the authors have read and approved the final version of the manuscript and agreed to be held accountable for all aspects of the work.

Conflict of interest: the authors declare no potential conflict of interest.

Funding: none.

Ethics approval and consent to participate: not applicable.

Consent to participate: written informed consent was obtained from the patients for the publication of this case report, including accompanying images.

Availability of data and materials: all data generated or analyzed during this study are included in this published article.

Received: 14 December 2023.

Accepted: 20 January 2024.

This work is licensed under a Creative Commons Attribution-NonCommercial 4.0 International License (CC BY-NC 4.0).

©Copyright: the Author(s), 2024

Licensee PAGEPress, Italy

Chest Disease Reports 2024; 12:12190

doi:10.4081/cdr.2024.12190

Publisher's note: all claims expressed in this article are solely those of the authors and do not necessarily represent those of their affiliated organizations, or those of the publisher, the editors and the reviewers. Any product that may be evaluated in this article or claim that may be made by its manufacturer is not guaranteed or endorsed by the publisher.

Introduction

Tuberculosis remains one of the most common infectious diseases, with 6.4 million new incident cases in the year 2021,¹ resulting in a total of 1.6 million deaths worldwide, which is next only to COVID-19 during that year.² Tuberculosis affects both sexes, though the proportion of males affected by tuberculosis is higher as compared to females.¹ However, its occurrence during pregnancy has detrimental effects on the well-being of the mother as well as the fetus.^{3,4} Among different types of tuberculosis, miliary tuberculosis remains one of the most fatal types as it is a disseminated disease with a hematogenous spread of infection to the lungs and other organs.⁵ The first description of miliary tuberculosis in *in vitro* Fertilization (IVF) pregnancy was published in the year 1988 by Addis *et al.*,⁶ though since then, several case reports of miliary tuberculosis in IVF pregnancy have been reported from different parts of the world.⁷⁻¹⁰ However, there is a complete lack of Indian studies. In the present study, we report a series of three military tuberculosis cases in IVF pregnancies at a super specialty respiratory care facility in India that have been reported in quick succession.

Case Report

Case #1

A 28-year-old female with IVF-induced pregnancy (amenorrhea for 18 weeks) with hypothyroidism was admitted to the Emergency Department with complaints of shortness of breath, fever, chills & rigors with palpitation for 10 days. At admission, the patient was conscious (GCS 15), with increased heart rate (140/min), normotensive (126/94 mmHg) and hyperthermic (102.4°F). The respiratory rate was 28/min, and the SpO₂ was 88% on room air with Bipap support 14/6. On examination, Respiratory system - B/L air entry decreased with tachypnoea; no other sys-

temic abnormality was seen. *Per-abdomen* uterus was 18 weeks in size. On Ultrasound Sonography (USG), fetal heartbeat was audible with anhydramnios. X-ray chest PA view with shield showed miliary deposits of 1-3 mm diameter nodules, uniform in size and uniformly distributed (Figure 1). The patient had a known history of hypothyroidism. On further investigation, drug-induced hyperthyroidism/thyrotoxicosis was detected. The USG was repeated after 2 days and showed an absence of fetal cardiac activity, with severe anhydramnios despite adequate interventions, and intrauterine fetal demise was reported. Termination of pregnancy was done with consent. The patient was placed on Anti-Tuberculosis Therapy (ATT) and was discharged after 9 days.

Case #2

A 31 years old female IVF-induced twin pregnancy of 22 weeks of gestation with a history of hypothyroidism (tab thyronorm 62.5 µg) was admitted to the Emergency Department with complaints of dry cough for two months, with shortness of breath and restlessness at night for 20 days. At the time of admission, the patient was fully conscious (GCS 15), had normal blood pressure and heart rate, mild hyperthermia (100.1°F), respiratory rate 28/min, SpO₂ 96% at room air, mild B/L pedal edema was present. On auscultation, B/L breath sounds were present and equal with crepts heard. No other systemic abnormality was revealed. *Per-abdomen* evaluation revealed a 22-week uterus, and USG showed twin gestation live pregnancy with anhydramnios. Fetal heartbeats were audible. X-ray chest PA view (with shield) shows miliary deposits of 1-3mm diameter nodules, uniform in size and uniformly distributed (Figure 2). ATT was started. However, the patient opted for discharge against medical advice, and over a telephone conversation, it was learned that the patient had expired later elsewhere during the course of treatment.

Case #3

A 32-year-old female IVF-induced pregnancy of 12 weeks of gestation with a history of hypothyroidism was admitted to the Emergency Department with complaints of fever for 15 days and shortness of breath for the last four days. At admission, the patient was fully conscious (GCS 15), heart rate was 130/min, blood pressure 110/70 mmHg, normothermic, respiratory rate 22/min, SpO₂ 96% on oxygen @2 lit/min. On examination, bilateral breath sounds with crepts were heard. No other systemic abnormality was seen. *Per-abdomen* examination revealed a uterus of 12 weeks in size. On USG, a single, live intrauterine pregnancy of 12 weeks was reported. X-ray chest PA view, with shield, showed miliary deposits of 1-3mm diameter nodules, uniform in size and uniformly distributed (Figure 3). ATT was started. The patient was discharged on day 5 after subsidization of symptoms. The patient carried the pregnancy and delivery at 27 weeks of gestation through the normal vaginal route. A female baby was born with low Apgar and cyanosis, requiring Neonatal Intensive Care Unit (NICU) admission, and eventually expired.

Discussion

Reports of miliary tuberculosis in IVF pregnancy are frequent.⁷⁻¹⁰ However, to the best of our knowledge, no case series has been reported from India. Most of the previous reports comprise a small series of patients and have specific findings that cannot be generalized. However, there are some large series that show prior

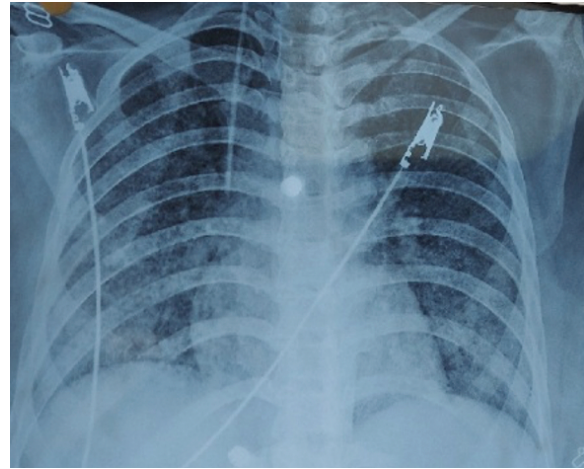


Figure 1. Patient 1. X-ray chest Posterior-Anterior (PA) view shows miliary deposits of 1-3 mm diameter nodules, uniform in size and uniformly distributed.

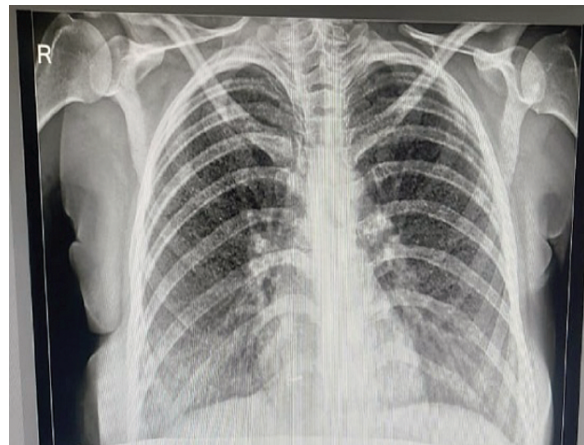


Figure 2. Patient 2. X-ray chest Posterior-Anterior (PA) view shows miliary deposits of 1-3mm diameter nodules, uniform in size and uniformly distributed.

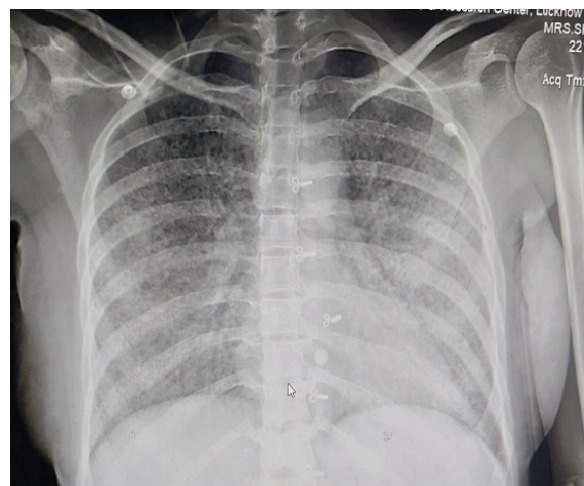


Figure 3. Patient 3. X-ray chest Posterior-Anterior (PA) view shows miliary deposits of 1-3mm diameter nodules, uniform in size and uniformly distributed.

history of tuberculosis in 10-15% of cases.^{8,9} In the present study, none of the cases have any such history. Most of the cases are recognized owing to symptomatic onset on chest radiology.⁷⁻¹⁰ In the present study, one patient expired, another underwent medical termination of pregnancy, and the last one ended up in a preterm birth leading to NICU admission of the baby, thus showing fatal and unfavorable outcomes in all the cases. Dong *et al.*, in their compilation of 75 cases, found fatal complications in 44% of cases.⁸ One common finding in all the patients in the present study was a history of hypothyroidism. Although hypothyroidism patients are known to have almost three times higher risk of developing tuberculosis.¹¹ However, no such report of miliary tuberculosis in IVF pregnancies could be retrieved by us.

Conclusions

The present study identifies hypothyroidism as a strong new risk factor. Given the fact that women undergoing IVF have an increased susceptibility to infections, particularly tuberculosis, before initiation of IVF treatment, a thorough history of tubercular contact and latent tuberculosis must be carried out.

References

1. World Health Organization (WHO). Global Tuberculosis Report. 2022. Available from: <https://www.who.int/teams/global-tuberculosis-programme/tb-reports/global-tuberculosis-report-2022>
2. World Health Organization (WHO). Fact Sheet on Tuberculosis. 2023. Available from: <https://www.who.int/news-room/fact-sheets/detail/tuberculosis>
3. Wang K, Ren D, Qiu Z, Li W. Clinical analysis of pregnancy complicated with miliary tuberculosis. *Ann Med.* 2022;54:71-9.
4. Bates M, Ahmed Y, Kapata N, et al. Perspectives on tuberculosis in pregnancy. *Int J Infect Dis.* 2015;32:124-7.
5. Vohra S, Dhaliwal HS. Miliary Tuberculosis. 2023. Available from: <https://www.ncbi.nlm.nih.gov/books/NBK562300/>
6. Addis GM, Anthony GS, d'A Semple P, Miller AW. Miliary tuberculosis in an in-vitro fertilization pregnancy: a case report. *Eur J Obstet Gynecol Reprod Biol.* 1988;27:351-3.
7. Hongbo L, Li Z. Miliary tuberculosis after in vitro fertilization and embryo transplantation. *Afr Health Sci.* 2015;15:701-4.
8. Dong S, Zhou R, Peng E, He R. Analysis of clinical features and risk factors in pregnant women with miliary pulmonary tuberculosis after in vitro fertilization embryo transfer. *Front Cell Infect Microbiol.* 2022;12:885865.
9. Gai X, Chi H, Cao W, et al. Acute miliary tuberculosis in pregnancy after in vitro fertilization and embryo transfer: a report of seven cases. *BMC Infect Dis.* 2021;21:913.
10. Ye R, Wang C, Zhao L, et al. Characteristics of miliary tuberculosis in pregnant women after in vitro fertilization and embryo transfer. *Int J Tuberc Lung Dis.* 2019;23:136-9.
11. Cheng LT, Chung CH, Peng CK, et al. Bidirectional relationship between tuberculosis and hypothyroidism: an 18-year nationwide population-based longitudinal cohort study. *Front Med (Lausanne).* 2022;9:900858.