

An unusual case of upper airway obstruction: what if it's not asthma?

Marco Umberto Scaramozzino,^{1,2,3} Veronica Nassisi,⁴ Giovanni Sapone⁵

¹Director, Ambulatory of Pulmonology “La Madonnina”, Reggio Calabria; ²Head, Thoracic Endoscopy Service, Villa Aurora Hospital, Reggio Calabria; ³Head, Thoracic Endoscopy Service, Tirrenia Hospital, Belvedere Marittimo (CS); ⁴Department of Clinical and Experimental Medicine, University of Messina; ⁵Head Nurse, Cardiology Department, Polyclinic “Madonna della Consolazione”, Reggio Calabria, Italy

Correspondence: Marco Umberto Scaramozzino, Director, Ambulatory of Pulmonology “La Madonnina”, Reggio Calabria, Italy.

Tel.+39.3283074746 - 0965.893920.

E-mail: scaramozzinomarco91@gmail.com

Key words: tracheal stenosis, asthma, bronchoscopy, endoscopic, observation.

Contributions: MUS and VN helped in the conception and design of the study; MUS and VN did data collection; MUS and VN did analysis and interpretation of data; MUS and VN contributed to drafting the work and revising it critically for important intellectual content; GS translated the paper to English. All authors approved the final version for publication and agreed to be accountable for all aspects of the work to ensure that questions related to the accuracy or integrity of any part of the work are appropriately investigated and resolved.

Conflict of interest: the authors declare no potential conflict of interest.

Funding: none.

Ethics approval and consent to participate: not applicable.

Patient's consent for publication: the patient gave her written consent to use her personal data for the publication of this case report and any accompanying images.

Availability of data and materials: all data generated or analyzed during this study are included in this published article.

Received: 4 December 2023.

Accepted: 23 January 2024.

Early view: 22 April 2024.

This work is licensed under a Creative Commons Attribution-NonCommercial 4.0 International License (CC BY-NC 4.0).

©Copyright: the Author(s), 2024

Licensee PAGEPress, Italy

Chest Disease Reports 2024; 12:12157

doi:10.4081/cdr.2024.12157

Publisher's note: all claims expressed in this article are solely those of the authors and do not necessarily represent those of their affiliated organizations, or those of the publisher, the editors and the reviewers. Any product that may be evaluated in this article or claim that may be made by its manufacturer is not guaranteed or endorsed by the publisher.

Abstract

Tracheal stenosis poses a diagnostic challenge that can mimic other respiratory pathologies, particularly bronchial asthma. It is characterized by a narrowing of the tracheal caliber, leading to respiratory symptoms such as dyspnea, cough, and wheezing. However, these manifestations can overlap with those of bronchial asthma, making the differential diagnosis a challenging yet crucial task for an appropriate therapeutic approach. This study aims to underscore the importance of a comprehensive clinical approach, utilizing bronchoscopy and global spirometry with bronchodilator reversibility testing, to differentiate tracheal stenosis from bronchial asthma, thereby contributing to accurate and timely surgical treatment. Bronchoscopy stands as a cornerstone in investigating tracheal stenosis, allowing for a direct assessment of the site, extent, and nature of the stenosis. Endoscopic observation of the morphological characteristics of the stenosis, such as concentric narrowing or mucosal irregularities, can guide towards a more precise diagnosis. Asthma, characterized by a reversible bronchial obstruction, responds positively to bronchodilators, whereas tracheal stenosis shows a limited or absent response.

Introduction

According to the Global Initiative for Asthma (GINA) 2023 document, bronchial asthma is a heterogeneous disease characterized mainly by chronic inflammation of the airways. It is defined by the history of respiratory symptoms such as wheezing, dyspnea, chest tightness, and cough, which vary in intensity over time, together with the variable limitation of airflow on exhalation, which may become persistent over time. It is usually associated with airway hyperresponsiveness and inflammation, but these features are neither necessary nor sufficient for the diagnosis. The diagnosis of asthma is based on the history of characteristic symptoms and the presence of variable airflow limitation during exhalation, which must be confirmed by bronchodilator reversibility testing or other tests.¹ Among the causes that must be carefully investigated during the diagnosis of asthma are obstructions in the central airways, which are part of the differential diagnosis with this pathology. Tracheal stenosis is among the causes that determine respiratory symptoms that simulate asthma. The use of tracheal sound frequency analysis has been considered a valid method for detecting tracheal stenosis, especially in patients with malignant tumors compressing the trachea. However, in patients with intrathoracic stenosis, abnormalities in lung function and tracheal sound spectra have been observed, even in the presence of less severe stenosis.² The diagnosis of tracheal stenosis requires a

precise diagnosis and expert operators in both endoscopy and surgical treatment, as demonstrated by case series analyses in the literature; furthermore, all patients underwent sequential spirometry and sequential endoscopic evaluation to understand the type of treatment to be used on a case-by-case basis.³

Case Report

The clinical case described concerns a 74-year-old Caucasian woman who came to my attention in September 2023 for a recent flu episode, accompanied by the persistence of dry cough, nocturnal symptoms, dyspnea, wheezing, and a sense of tightness in the chest, and no previous symptoms referred by the patient. The clinical history included drug allergy to penicillin since childhood, arterial hypertension, and episodes of tachycardia treated with propranolol. No alterations in laboratory tests, blood count, and immunoglobulin E dosage. After a careful medical examination, which turned out to be negative for significant pulmonary findings on physical examination and peripheral oxygen saturation values in ambient air were normal (97%), I took a look at the chest Computed Tomography (CT) scan of October 2023 and July 2023, which highlighted thyroid enlargement which, in my opinion, determines an extrinsic compression on the trachea (Figure 1A, B), with also the presence of high mediastinal lymphadenopathies. We carried out global spirometry with PulmOne MiniBox+©, which showed a mild non-reversible obstructive deficit after the bronchodilation test with 400 micrograms of salbutamol and the appearance of the flow-volume curve characterized by a plateau in the expiratory phase, caused by an extrathoracic obstruction affecting the upper airways and altered Motley Index (Figure 2). The finding needed to be evaluated by an endocrinologist, as the lady already had a clinical history of nodular goiter. A suspected diagnosis of bronchial asthma was first formulated, with the possibility of an extrathoracic condition that could have compressed the trachea, simulating asthma. The proposed treatment consisted of stopping propranolol and starting bisoprolol, together with a new therapeutic regimen that included a Dry-Powdered Inhaler (DPI) inhaled drug (fluticasone furoate/vilanterol 92/22 micrograms) and an antibiotic (azithromycin) for a few days, with a recommendation to return for follow-up clinical and spirometric during inhalation therapy. Further instrumental and clinical tests were recommended to monitor the response to therapy and delve deeper into the patient's endocrinological situation, especially in relation to tracheal closure. Despite the therapy carried out and other clinical investigations carried out, which were negative, the lady at the

clinical check-up one month into the course of regular therapy presented the same symptoms without further clinical and spirometric improvement. She repeated the chest CT scan, which confirmed the suspicion of upper airway pathology, and was indicated to perform a bronchoscopy. At bronchoscopy, there was evidence of a 90% occlusion of the upper 3rd of the trachea (Figure 3A), which was difficult to cross with the instrument and mediastinal compression on the tracheal tissue as visible in the second photo (Figure 3B). The images were taken with an Olympus BF H190© bronchoscope, which presents the possibility of using Narrow Band Imaging (NBI) to evaluate head, neck, and gastroenterological tumors. The exploratory examination was not conducted beyond the tracheal tissue (Figure 3), as the patient had significant desaturations (up to 85%) under anesthesia with midazolam 2.5 milligrams

Discussion

One of the causes that were investigated by the endocrinologist was extensive intrathoracic goiter, which normally causes compression of the trachea and for which it is necessary to intervene surgically, as indicated in a case report in the literature, with the removal of the mass without damaging crucial nerves or blood vessels.⁴ However, in this case, the endocrinologist specialist colleague ruled it out with a thyroid ultrasound, which, in his opinion, was negative. In this case, despite the radiological evidence on computed tomography, which showed massive enlargement of both thyroid lobes with evidence of endobronchial tissue, it was not possible to carry out a retrograde bronchoscopy as carried out in a case report in the literature to fully confirm the stenosis.⁵ However, a strong suspicion remained, which allowed the pulmonologist specialist to refer the patient for surgical evaluation. To manage such significant tracheal stenosis endoscopically, endoscopic techniques, such as balloon dilation, would be required, which are becoming more common in treating stenotic lesions previously thought to be suitable only for open surgical procedures. Among the possible additional treatments currently under discussion are the use of stents, regenerative therapy, and adjuvant pharmacological therapies such as aerosolized topical steroids. In this specific case, unfortunately, the structure did not have the necessary equipment to carry out this treatment.⁶

There is a case report in the literature involving the use of intravenous anesthesia with airway management using a thin endotracheal tube (Tritube) and a high oxygen flow rate ventilation technique (STRIVE-Hi) in tracheal masses. After the tumor has

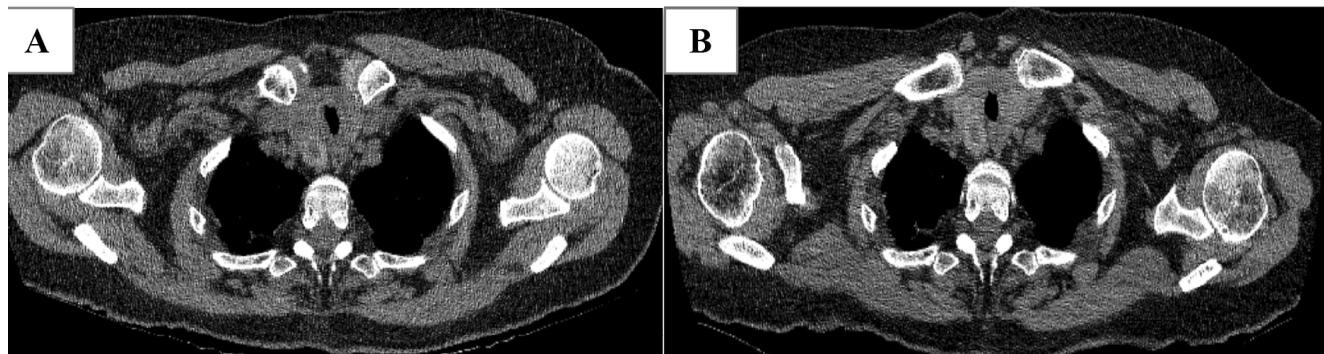

Figure 1. **A)** Computed Tomography (CT) scan of July 2023. **B)** CT scan of October 2023 after treatment with ICS/LABA for one month. ICS, Inhaled Corticosteroids; LABA, Long-Acting Beta-2-Agonist.

been removed, the Tritube is replaced with a hose endotracheal tube to ensure the correct ventilation and oxygenation of the patient.⁷ Thyroid cancer is often asymptomatic until tumor invasion reaches the mucosal surface. When this happens, bloody expectoration and shortness of breath may occur. Treatment is based on the site, depth, and extent of the invasion. Unlike tumors that originate from the tracheal mucosa, in thyroid cancer, the invasion begins outside the airways and progresses towards the light,

making it difficult to diagnose the precise extent of the invasion even with bronchoscopy, as can partly be documented in this case.⁸ Bronchoscopy helps the clinician, showing in some cases paralysis of the right vocal cord but no tumor or inflamed lesion in the larynx or pharynx; in this specific case, there was no evidence of alterations during the passage of the bronchoscope.⁹ The differential diagnoses that will subsequently be conducted by the thoracic surgeon include sarcoidosis, amyloidosis, idiopathic subglottic and

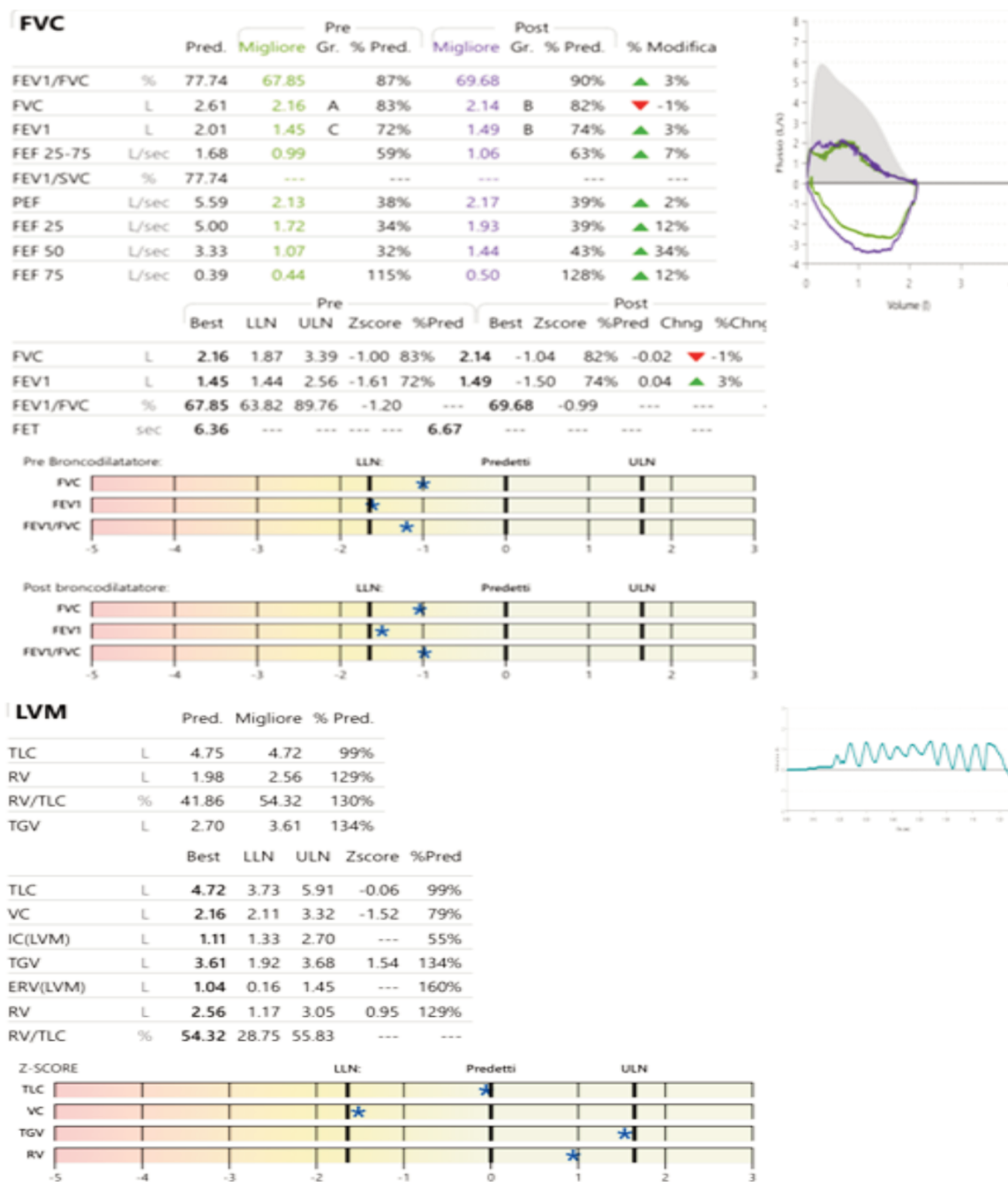


Figure 2. Global spirometry with PulmOne MiniBox+ © which showed: Mild non-reversible obstructive deficit (FEV1: 72%→74% FVC: 83%→82% FEV1/FVC: 87%→90% PEF: 38%→39%, RV: 129% RV/TLC: 130%) after bronchodilation test with salbutamol and appearance of the flow-volume curve characterized by a plateau in the expiratory phase, caused by an extrathoracic obstruction affecting the upper airways and altered Motley Index. FEV1, Maximum Expiratory Volume at first second; FVC, Forced Vital Capacity; FEV1/FVC%, Index of Tiffeneau; PEF%: Percentage of Peak of Expiratory Flow; RV, Residual Volume; RV/TLC%: Motley Index.

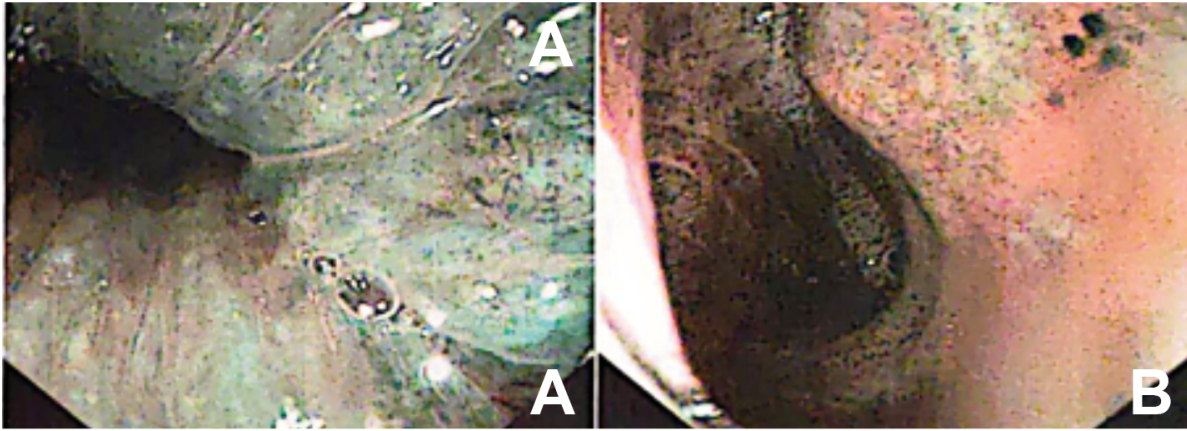


Figure 3. Images captured from Olympus BF H190© bronchoscope, which presents the possibility of using Narrow Band Imaging (NBI) to evaluate head and neck and gastroenterological tumors. **A)** there was evidence of a 90% occlusion of the upper 3rd of the trachea, which was difficult to cross with the instrument and mediastinal compression on the tracheal tissue as visible in the second photo **(B)**.

tracheal stenosis in Multifocal Fibrosclerosis (MFS), and Wegener's Granulomatosis (WG); which however is less common as a tracheal presentation.^{10,11} A clinical study examines the effectiveness of interventional bronchoscopic procedures in the treatment of severe tracheal obstruction caused by thyroid disease, both benign and malignant. The study design is a retrospective analysis of a cohort of patients treated at a university hospital center. Outcomes of bronchoscopy procedures were evaluated, including subjective improvement, pulmonary function tests, early and late complications, and survival. The procedures involved dilation, stent placement, and/or Nd-YAG laser treatment. Relief after treatment was immediate and long-term in 88% of patients with benign pathologies and in 92% of patients with malignant pathologies. Complications were manageable, and median survival was 540 days for malignant patients¹²

Conclusions

The article examines the challenge of diagnosing tracheal stenosis, often camouflaged by bronchial asthma, highlighting the importance of differentiation via bronchoscopy and spirometry. Describes the case of a patient with suspected tracheal stenosis, manifesting asthma-like symptoms. Despite therapy, symptoms persist, suggesting an uncertain diagnosis. The discussion highlights the complexity of the diagnosis, requiring endoscopic procedures and advanced therapies for the effective management of tracheal stenosis. He concludes by underlining the importance of in-depth specialist assessments and advanced diagnostic techniques for precise diagnosis and optimal treatment. The situation highlights the challenges in the differential diagnosis and therapeutic approach of tracheal stenosis, encouraging more in-depth research for more effective management of similar cases.

References

1. Global Initiative for Asthma. Global Strategy for Asthma Management and Prevention, 2023. 2023. Available from: www.ginasthma.org
2. Yonemaru M, Kikuchi K, Mori M, et al. Detection of tracheal stenosis by frequency analysis of tracheal sounds. *J Appl Physiol.* 1993;75:605-12.
3. Alvarez-Maldonado P, Peña J, Criales-Cortés JL, et al. Benign tracheal stenosis: a case series analysis. *J Bronchology Interv Pulmonol.* 2009;16:254-60.
4. Nakamura R, Okuda K, Chiba K, et al. A large intrathoracic goiter with tracheal stenosis: complete resection using a robot-assisted thoracoscopic approach. *Thorac Cancer.* 2022;13:1874-7.
5. Eloy JA, Omerhodzic S, Yuan S, et al. Extended tracheal stenosis secondary to a massive substernal goiter. *Thyroid.* 2007;17:899-900.
6. Brigger MT, Boseley ME. Management of tracheal stenosis. *Curr Opin Otolaryngol Head Neck Surg.* 2012;20:491-6.
7. Shallick N, Elarref M, Khamash O, et al. Management of critical tracheal stenosis with a straw-sized tube (Tritube): case report. *Qatar Med J.* 2021;2020:48.
8. Tsutsui H, Tamura A, Ito J, et al. Surgery for thyroid cancer invading the trachea. *Indian J Surg Oncol.* 2022;13:184-90.
9. Kusunoki T, Homma H, Kidokoro Y, et al. Tracheal stenosis and recurrent nerve paralysis due to thyroid malignant lymphoma with huge chronic thyroiditis. *Clin Pract.* 2020;10:1276.
10. Orabi AA, Negam A, Bulman C. Subglottic and tracheal stenosis associated with multifocal fibrosclerosis. *Acta Otolaryngol.* 2007;127:662-6.
11. Zycinska K, Wardyn K, Zielonka TM, et al. Subglottic and tracheal stenosis due to Wegener's granulomatosis. *Adv Exp Med Biol.* 2013;755:221-4.
12. Noppen M, Poppe K, D'Haese J, et al. Interventional bronchoscopy for treatment of tracheal obstruction secondary to benign or malignant thyroid disease. *Chest.* 2004;125:723-30.