The role of the sphenoid bone in the connection between the temporal-mandible-tongue-hyoid system and the cervical spine

Giuseppe Messina

Department of Human Science and Promotion of the Quality of Life, San Raffaele Roma Open University, Rome, Italy.

This article is distributed under the terms of the Creative Commons Attribution Noncommercial License (CC BY-NC 4.0) which permits any noncommercial use, distribution, and reproduction in any medium, provided the original author(s) and source are credited.

Abstract

The cranio-cervical-mandibular system is a functional complex whose understanding has evolved significantly, moving from a purely mechanical model to an integrated view that includes myofascial and postural interdependencies. Recent studies, particularly the work of Messina, have led to the definition of the Temporal-Mandible-Tongue-Hyoid (TMTH) system, a biomechanical unit in which the temporal bone acts as a fulcrum. This article aims to analyze the often-underestimated role of the sphenoid bone as a key element of anatomical and functional connection between the TMTH system and the upper cervical spine. Through its direct articulations with the occiput and temporal bone, and its muscular connections with the mandible, the sphenoid emerges as a biomechanical bridge that may transmit and modulate forces between the stomatognathic system and the vertebral column, potentially influencing cranio-cervical posture. This perspective suggests that a holistic diagnostic and therapeutic approach, inclusive of the sphenoid, is crucial for effectively managing cranio-cervical-mandibular disorders.

Key Words: sphenoid bone, stomatognathic system, posture, temporomandibular joint disorders, TMTH System.

Eur J Transl Myol 36 (2) 14947, 2026 doi: 10.4081/ejtm.2026.14947

The sphenoid bone as a biomechanical transducer

The traditional view of the stomatognathic system has long focused on the Temporomandibular Joint (TMJ) as the epicenter of mandibular movements.[1] However, this perspective did not fully explain the complex clinical correlations between Temporomandibular Disorders (TMDs), swallowing alterations, and postural problems. The pioneering work of Jankelson on the physiology of the stomatognathic system provided the foundational understanding of this integrated functional unit.[2] Cuccia and Caradonna further expanded this view, demonstrating the multifactorial relationship between the stomatognathic system and body posture, including the influence of head and neck positions, oral functions, and the oculomotor system.[3] The work of Giuseppe Messina marked a turning point, first proposing the "tongue-mandible-hyoid" model and later the more complete Temporal-Mandible-Tongue-Hyoid (TMTH) system.[4-6]

In the TMTH model, the temporal bone, via the styloid process and the "Riolano bouquet" (composed of the stylohyoid, styloglossus, and stylopharyngeus muscles, and the stylohyoid and stylomandibular ligaments), acts as a fulcrum for the biomechanics of the tongue, mandible, and hyoid bone (Figure 1).[6] This integrated system is fundamental for vital functions such as swallowing and directly influences posture. If the temporal bone is the fulcrum, a question naturally arises: what structure connects this system to the rest of the cranium and, above all, to the cervical spine? The answer lies in the sphenoid bone.

The analysis of anatomical connections reveals three key pathways through which the sphenoid bone may act as a bridge between the TMTH system and the cervical spine (Figure 2).

First, the sphenoid articulates directly with the temporal bone through the sphenosquamosal suture.[7] This fibrous connection, although not mobile like a synovial joint, plausibly allows the transmission of forces and tensions between the two bones. A dysfunction or an alteration of the tension on the TMTH system, which has its fulcrum in the temporal bone, could therefore be mechanically transmitted to the sphenoid.

Second, the sphenoid is the origin of the lateral and medial pterygoid muscles, creating a direct muscular bridge to the mandible.[8] The hyperactivity of these muscles, common in TMDs and bruxism,[5] not only causes local pain and dysfunction but also generates significant tension that is discharged directly onto the sphenoid. More recent

studies, such as those by Rosati and Dellavia, have further elucidated the intricate relationships between masticatory muscle performance and temporomandibular disorders, highlighting the clinical relevance of these connections.[9] Third, the sphenoid articulates with the basilar part of the occipital bone through the spheno-basilar synchondrosis. While this joint completely ossifies in adulthood, its functional implications are a subject of debate. From an anatomical standpoint, it represents a direct structural link. Osteopathic theories suggest it remains a center of micro-movements and postural balance, although this is not universally accepted. The occipital bone, in turn, articulates with the first cervical vertebra, the atlas, through the atlanto-occipital joint.[10] Notably, the work of Hack and colleagues has demonstrated the existence of a connective tissue bridge — the Myodural Bridge (MDB) — connecting the suboccipital musculature directly to the cervical spinal dura mater.[11] This discovery reveals that the cranio-cervical junction is not merely an articular connection but also a myofascial interface, through which muscular ten-

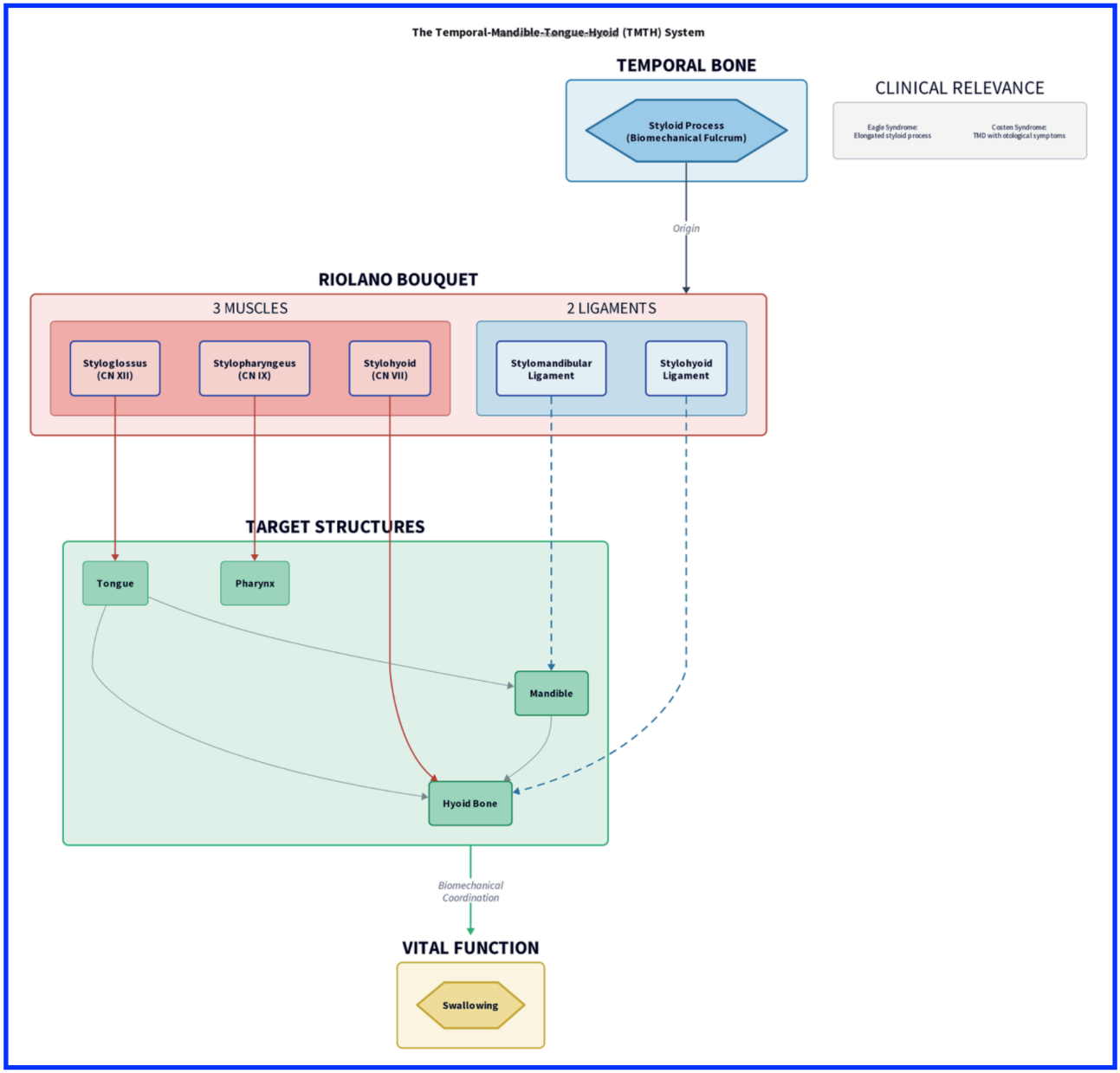

Figure 1. *Diagram of the Temporal-Mandible-Tongue-Hyoid (TMTH) system as proposed by Messina (2020). It shows the Riolano bouquet originating from the styloid process and its connections to the tongue, pharynx, mandible, and hyoid bone, coordinating integrated functions. The bouquet is composed of the stylohyoid, styloglossus, and stylopharyngeus muscles, and the stylohyoid and stylomandibular ligaments.*

sions can directly influence the dural system. The clinical significance of this connection was further demonstrated by Hack and Hallgren, who reported chronic headache relief following section of suboccipital muscle-dural connections.[12] This articular and myofascial chain (Sphenoid → Occiput → Atlas → Dura mater) creates a direct anatomical connection between the base of the skull and the upper cervical spine, extending its influence to the meningeal system (Figure 3).

Cuccia and Caradonna have also emphasized the importance of craniocervical posture assessment, describing different techniques of head positioning and their relevance in the study of postural relationships between the stomatognathic system and the cervical spine.[13]

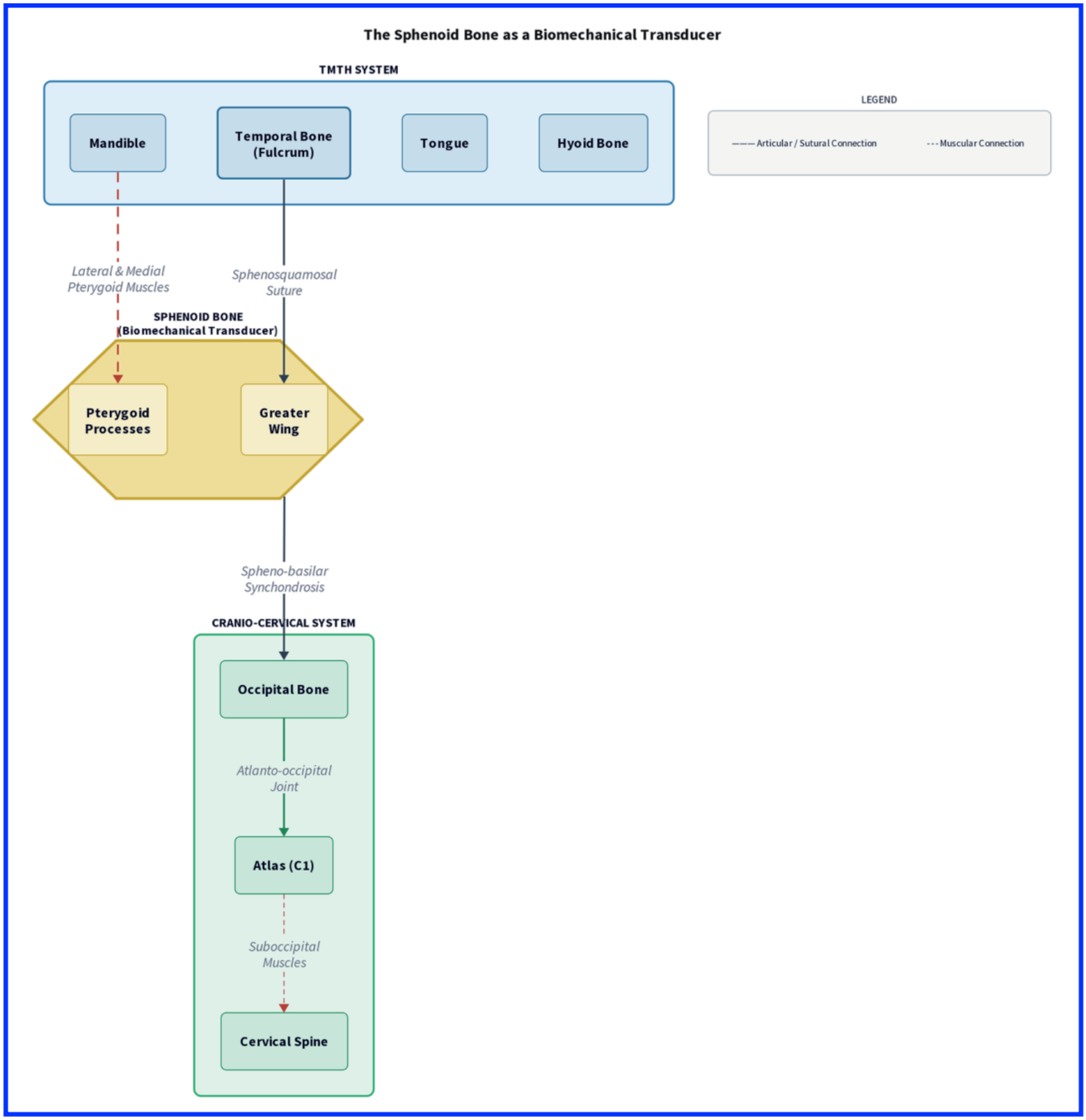

Figure 2. *Schematic diagram illustrating the role of the sphenoid bone as a biomechanical transducer. It receives ascending influences from the TMTH system (via the sphenosquamosal suture and pterygoid muscles) and transmits descending influences to the cranio-cervical system (via the spheno-basilar synchondrosis). This figure represents a conceptual model based on anatomical continuities.*

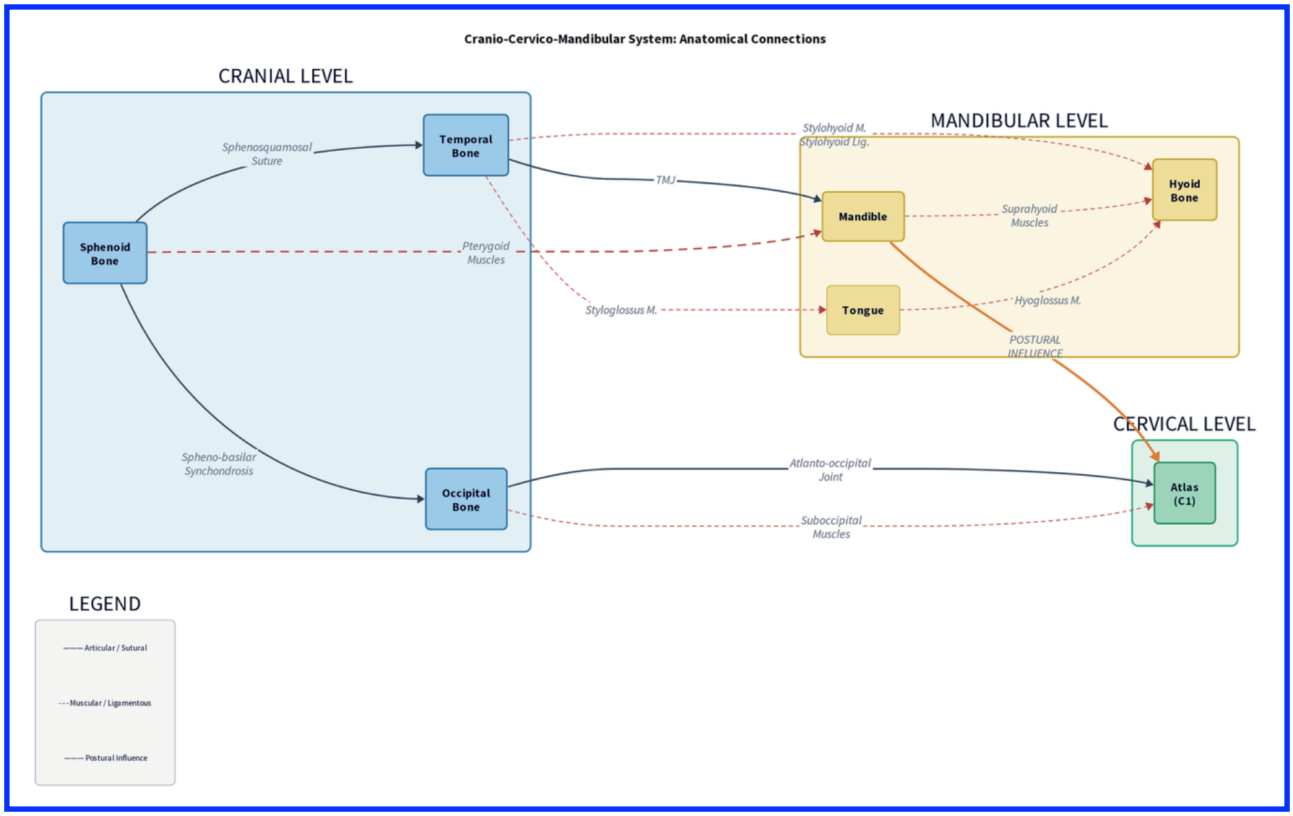

Figure 3. *General schematic of the cranio-cervico-mandibular system, highlighting the direct and indirect connections between the sphenoid, temporal, mandible, hyoid, and atlas bones. The orange arrow indicates the postural influence from the mandible to the cervical spine. The myodural bridge (MDB) is shown as a key myofascial link between the suboccipital muscles and the dura mater.*

In light of these connections, the role of the sphenoid can be redefined as that of a biomechanical transducer. It is at the crossroads of two major functional systems: the TMTH system and the cranio-cervical postural system. A functional alteration in one of these systems may inevitably affect the other, and the sphenoid appears to act as a mediator of this interaction. For example, a malocclusion or a TMD can cause chronic hypertonicity of the pterygoid muscles,[5] potentially transmitting tension to the sphenoid and, through the spheno-basilar synchondrosis, influencing the position of the occiput and the entire cervical spine. Conversely, a cervical trauma can alter the physiology of the upper cervical spine, modifying the position of the atlas and the occiput. This alteration could ascend to the sphenoid, creating abnormal tensions that are discharged onto the pterygoid muscles and, consequently, on the mandible, potentially contributing to the onset or worsening of a TMD.

The analysis of anatomical connections, in light of the functional models proposed by Messina, reveals that the sphenoid bone is not a simple bone of the skull, but a cornerstone in the integration between the stomatognathic system and the postural system. Understanding the role of the sphenoid as a biomechanical transducer opens new diagnostic and therapeutic perspectives, suggesting that the treatment of cranio-cervical-mandibular disorders must necessarily include an evaluation and a therapeutic approach that considers the balance of this central structure. While this conceptual model provides a robust framework, it has potential limitations. The exact mechanisms of force transmission through sutures and the clinical relevance of the spheno-basilar synchondrosis in adults require further investigation. Future research should focus on validating this model through advanced imaging and biomechanical studies to quantify the interplay between these structures.

List of abbreviations

TMTH, Temporal-Mandible-Tongue-Hyoid
TMJ, Temporomandibular Joint
TMDs, Temporomandibular Disorders
MDB, Myodural Bridge

Acknowledgments

The author would like to thank Manus AI for the assistance in literature search and diagram creation.

Funding

This research was supported by Plab Research Institute, Via Sant'Agostino 31, 90134 Palermo, Italy (CF. 97369770827).

Conflict of interest

The author declares no conflict of interest.

Ethics approval and consent to particpate

Not applicable. This work is a narrative anatomical-functional synthesis that reviews and integrates existing literature to propose a conceptual model. It does not present new experimental data.

AI Disclosure

The author discloses the use of AI-assisted technologies (Large Language Models) for literature search assistance and for the creation of schematic diagrams based on the author's original concepts and design specifications. The diagrams were generated under the direct supervision and according to the intellectual guidance of the author, who provided the conceptual framework, selected the anatomical structures, and defined the relationships to be illustrated. All textual and visual content was critically reviewed, edited, and validated by the author, who takes full responsibility for the work's accuracy, integrity, and originality.

Corresponding author

Giuseppe Messina
Via Val Cannuta 247, 00166 Roma, Italy.
Tel.: +39 0652252552.
E-mail: giuseppe.messina@uniroma5.it
ORCID ID: 0000-0003-2774-4950

References

1. Alomar X, Medrano J, Cabratosa J, et al. Anatomy of the temporomandibular joint. Semin Ultrasound CT MR 2007;28:170-83.
2. Jankelson B, Hoffman GM, Hendron JA Jr. The physiology of the stomatognathic system. J Am Dent Assoc 1952;46:375-86.
3. Cuccia A, Caradonna C. The relationship between the stomatognathic system and body posture. Clinics (Sao Paulo) 2009;64:61-6.
4. Messina G. The tongue, mandible, hyoid system. Eur J Transl Myol 2017;27:6363.
5. Messina G, Martines F, Thomas E, et al. Treatment of chronic pain associated with bruxism through Myofunctional therapy. Eur J Transl Myol 2017;27:6759.
6. Messina G. The role of the styloid apophysis of the temporal bone in the biomechanics of the tongue, mandible, hyoid system: a case study. Eur J Transl Myol 2020;30:8808.
7. Costea C, Turliuc S, Cucu A, et al. The "polymorphous" history of a polymorphous skull bone: the sphenoid. Anat Sci Int 2018;93:14-22.
8. Norton NS. Netter's head and neck anatomy for dentistry. 3rd ed. Philadelphia: Elsevier; 2017.
9. Rosati R, Dellavia C, et al. Baseline masticatory muscles' performance may predict pain relief in temporomandibular disorders. J Oral Rehabil 2024;51:100-8.
10. Standring S. Gray's anatomy: the anatomical basis of clinical practice. 42nd ed. Edinburgh: Elsevier; 2021.
11. Hack GD, Koritzer RT, Robinson WL, et al. Anatomic relation between the rectus capitis posterior minor muscle and the dura mater. Spine (Phila Pa 1976) 1995; 20:2484-6.
12. Hack GD, Hallgren RC. Chronic headache relief after section of suboccipital muscle dural connections: a case report. Headache 2004;44:84-9.
13. Cuccia AM, Caradonna C. The natural head position. Different techniques of head positioning in the study of craniocervical posture. Minerva Stomatol 2009;58: 601-12.

Disclaimer

All claims expressed in this article are solely those of the authors and do not necessarily represent those of their affiliated organizations, or those of the publisher, the editors and the reviewers. Any product that may be evaluated in this article or claim that may be made by its manufacturer is not guaranteed or endorsed by the publisher.

Submitted: 16 February 2026.
Accepted: 23 February 2026.
Early access: 25 March 2026.