

A comparative study of sutureless versus sutured transperitoneal laparoscopic ureterolithotomy for large proximal ureteral stones: Efficacy, safety, and perioperative outcomes

Seyed Ali Eslahi¹, Seyed Hossein Hosseini¹, Iman Shamohammadi¹, Ali Akbarian¹, Ali Adib¹, Mazen Karama², Faisal Ahmed³

¹ Department of Urology, Faculty of Medicine, Shiraz University of Medical Sciences, Shiraz, Iran;

² Urology Department, Faculty of Medicine, Aden University, Aden, Yemen;

³ Department of Urology, Faculty of Medicine, Ibb University, Ibb, Yemen.

Summary

Background: Laparoscopic ureterolithotomy (LU) is a standard intervention for large proximal ureteral stones. A significant technical consideration is whether to suture the ureterotomy site or utilize a sutureless approach to potentially minimize operative time and surgical morbidity. This study aimed to compare the perioperative outcomes and safety profiles of sutureless versus conventional sutured transperitoneal LU.

Methods: We conducted a retrospective comparative study of 60 patients with proximal ureteral stones > 15 mm who underwent transperitoneal LU between January 2023 and March 2025. Patients were divided into two groups: a sutured group (n = 30), where the ureterotomy was closed with interrupted sutures, and a sutureless group (n = 30), where the site was left unsutured over a Double-J stent. Primary and secondary outcomes included operative time, urinary leakage volume (measured via drain output), hospital stay, and postoperative renal function.

Results: Baseline demographics and stone characteristics were comparable between the groups. The sutureless technique was associated with a significantly shorter mean operative time (2.2 ± 0.3 hours vs. 2.7 ± 0.4 hours; $p < 0.001$). While the duration of ureteral stenting was statistically longer in the sutureless group (17.7 ± 4.4 days vs. 16.1 ± 5.2 days; $p = 0.050$), this difference was clinically marginal. There were no significant differences in the volume of postoperative urinary leakage ($p = 0.066$), hospital stay, or changes in serum creatinine and hemoglobin levels. No cases of urinoma or ureteral stricture were observed in either cohort during the early follow-up period.

Conclusions: The sutureless technique for laparoscopic ureterolithotomy is a safe and efficient alternative that significantly reduces operative time without increasing the risk of major complications. Although it involves a statistically longer stenting period, the overall clinical outcomes are comparable to the sutured technique. The choice of approach should be individualized based on surgeon expertise and patient-specific anatomical factors.

KEY WORDS: Laparoscopic ureterolithotomy; Sutureless technique; Proximal ureteral stones; Surgical outcomes; Ureteral stent.

Submitted 31 December 2026; Accepted 31 January 2026

INTRODUCTION

Urolithiasis represents one of the most prevalent disorders of the urinary system, constituting a significant global health concern with substantial implications for patient quality of life and healthcare resources (1). The prevalence of kidney stones shows considerable geographical variation, ranging from 1% to 13% worldwide, with demographic factors such as age, sex, and race influencing its distribution (1, 2). In Iran, recent epidemiological studies indicate a high prevalence, affecting between 17% to 21% of the population, underscoring its clinical importance within the national context (3). Furthermore, the characteristically high recurrence rate of this disease amplifies the necessity for effective and efficient management strategies to mitigate its associated economic burden and patient morbidity (4).

Among the various presentations of urolithiasis, ureteral stones are particularly common and are a frequent cause of acute urological emergencies. These stones typically originate in the kidney and migrate into the ureter, where they can cause obstruction, leading to the classic symptoms of renal colic, hematuria, nausea, and vomiting (2). Without timely intervention, such obstruction risks serious complications, including hydronephrosis, irreversible renal impairment, and urosepsis. The management of ureteral stones is guided by factors such as stone size, location, and patient symptomatology (5). While medical expulsive therapy and minimally invasive procedures like extracorporeal shock wave lithotripsy (SWL) and ureteroscopy (URS) are first-line options for many stones, larger or impacted proximal ureteral stones often require more definitive surgical intervention (6, 7).

In recent decades, laparoscopic ureterolithotomy has emerged as a highly effective minimally invasive approach for managing such complex stones. This technique offers advantages over traditional open surgery, including reduced postoperative pain, shorter hospital stays, and more rapid recovery (5, 7-9). Within the realm of laparoscopic ureterolithotomy, a technical nuance that remains a subject of debate is the management of the ureterotomy

incision after stone extraction. The conventional approach involves suturing the ureterotomy closed over a ureteral stent (7, 10). However, a sutureless technique, where the ureterotomy is left open with only a stent in place, has been proposed as a means to further simplify the procedure. Proponents hypothesize that omitting the suturing step could reduce operative time and potential suture-related complications, though concerns regarding urinary leakage and healing persist (9, 11, 12).

Thus, the comparative efficacy and safety of these two techniques necessitate rigorous evaluation. While some studies have explored the necessity of ureteral stenting post-ureterolithotomy (5, 9, 10), the specific impact of suturing versus a sutureless approach on operative outcomes requires further elucidation.

This study, therefore, aims to perform a comparative analysis of the outcomes and complications associated with sutureless transperitoneal laparoscopic ureterolithotomy versus the conventional sutured technique, with the goal of informing evidence-based surgical decision-making.

PATIENTS AND MATERIALS

Study design and setting

We conducted a retrospective, cross-sectional analysis of patients treated at three tertiary urology referral centers – Namazi, Faghihi, and Ali-Asghar Hospitals – between January 2023 and March 2025. The study evaluates the comparative outcomes of transperitoneal laparoscopic ureterolithotomy (LU) for proximal ureteral stones, focusing on the technical impact of omitting ureteral suturing. Data were systematically extracted from medical records using a standardized collection protocol to ensure intra-institutional consistency. The assignment to the sutured or sutureless technique was non-randomized and depended on the operating surgeon's intraoperative judgment and preference during the study period.

Study population and sample size

The target population comprised adult patients (aged ≥ 18 years) diagnosed with a single, large (> 15 mm) proximal ureteral stone that was refractory to conservative management, medical expulsive therapy, or prior ESWL (≤ 20 mm if prior ESWL failure).

To ensure statistical power, the sample size was calculated using G*Power software (Version 3.1.9.7). Based on a projected *minimum clinically important difference* (MCID) of 20 minutes in operative time (supported by prior studies showing 15-30-minute reductions with sutureless techniques; estimated pooled SD of 25 minutes (11, 13-15)), with $\alpha = 0.05$ and power $(1-\beta) = 0.80$, a minimum of 25 patients per group was required (effect size $d = 0.80$).

We enrolled 30 patients per cohort (total $N = 60$) to accommodate potential outliers and a 15-20% attrition rate, thereby enhancing the overall reliability and robustness of the comparative analysis.

Inclusion criteria

- Age ≥ 18 years with symptom duration > 1 month.
- Single proximal ureteral stone (between ureteropelvic

junction and upper sacroiliac joint border) measuring 10-20 mm, confirmed by non-contrast CT, KUB+IVU, or ultrasound.

- Negative preoperative urine culture. If positive, patients received culture-directed oral antibiotics (typically fluoroquinolone or cephalosporin) for 5-7 days, with surgery scheduled only after repeat culture confirmed sterility, normal WBC and CRP, and no active fever or leukocytosis $> 12,000/\mu\text{L}$.
- *American Society of Anesthesiologists* (ASA) score ≤ 3 , suitable for general anesthesia.

Exclusion criteria

We excluded patients with prior ipsilateral ureteral surgery, previous open abdominal/pelvic procedures, previous documented ureteral stricture, active/untreated urinary tract infection, uncorrected coagulopathy (platelets $< 100,000/\mu\text{L}$ or INR > 1.5), concomitant renal calculi or complex staghorn stones, solitary kidney, pyonephrosis (distinguished from hydronephrosis by the presence of clinical signs of infection such as fever $> 38^\circ\text{C}$, laboratory evidence of systemic inflammation, or specific imaging findings on CT/ultrasound suggestive of infected hydronephrosis), ureteropelvic junction obstruction, ureteral stricture, horseshoe/pelvic kidney, significant congenital urinary tract anomalies, BMI > 35 kg/m², pregnancy, or severe comorbidities (e.g., uncontrolled cardiovascular/respiratory disease, serum creatinine > 1.5 mg/dL, severe liver/kidney dysfunction).

Surgical technique

Preoperative evaluation included clinical history, routine laboratory panels (serum creatinine, BUN, hemoglobin), and non-contrast CT imaging to map stone characteristics. A single 1-gram dose of intravenous ceftriaxone was administered for surgical prophylaxis.

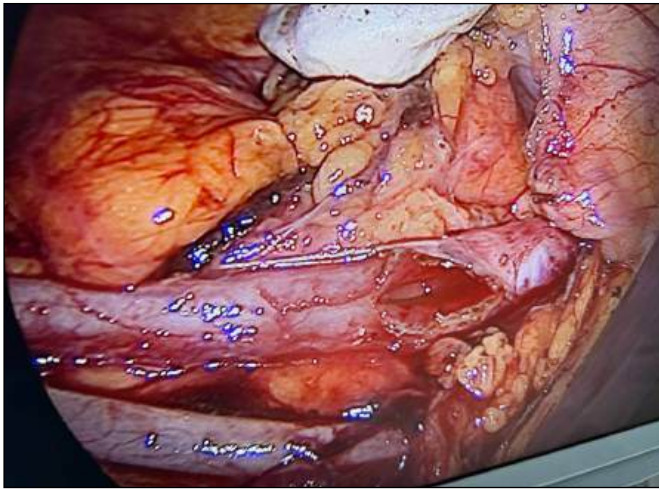
All procedures were performed by a consistent team of experienced laparoscopic urologists. Under general anesthesia, patients were placed in the supine position. A standard transperitoneal approach was utilized, employing a 10-12 mm umbilical camera port and two 5 mm working ports in the ipsilateral quadrants. For left-sided procedures, the descending colon was mobilized medially along the line of Toldt. For right-sided procedures, a similar medial mobilization of the ascending colon and hepatic flexure was performed. The ureter was identified as it crossed the iliac vessels. Following the identification of the ureter and the impacted stone, a longitudinal ureterotomy was performed using laparoscopic scissors. Once the stone was extracted, an antegrade *Double-J* (DJ) stent was placed under direct vision. A 10Fr *Jackson-Pratt* (JP) closed-suction drain was placed in the retroperitoneal space adjacent to the ureterotomy site and brought out through one of the 5-mm auxiliary ports. The drain was connected to a bulb suction device maintained on continuous gentle suction postoperatively.

Patients were managed according to two distinct closure techniques:

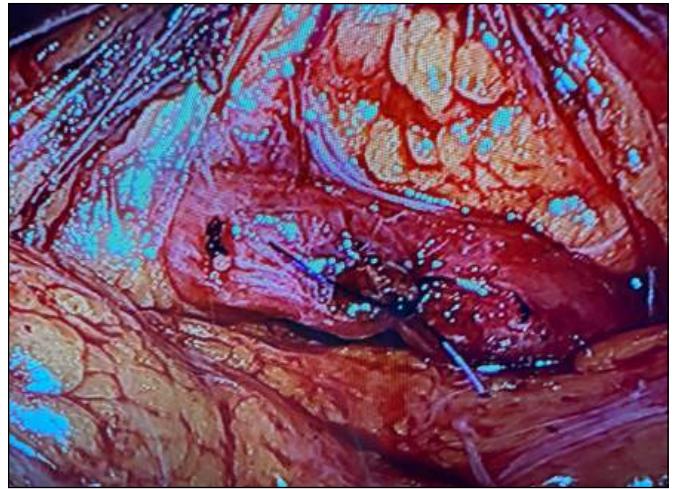
1. *Sutured Group*: The ureterotomy was primarily closed over the DJ stent using 4-0 interrupted monofilament absorbable sutures.
2. *Sutureless Group*: The ureterotomy was left unsutured

Figure 1A.

Intraoperative view of Sutureless technique following stone extraction. The ureterotomy is left unsutured over the internal Double-J stent (Black arrow).

**Figure 1B.**

Conventional suturing technique showing interrupted 4-0 absorbable sutures closing the ureterotomy (Black arrow).



to heal spontaneously over the DJ stent, which served as an internal scaffold for mucosal regeneration (Figure 1A-B).

Postoperative management and outcome measures

The urethral catheter was typically removed on the second or third postoperative day. The JP drain was monitored daily and removed once the output decreased to < 20 mL over 24 hours, provided that follow-up ultrasonography confirmed no significant fluid collections. The DJ stent was removed cystoscopically on an outpatient basis, generally between 14- and 21-days post-surgery.

The primary outcome measure was total operative time (from initial incision to skin closure). Secondary outcomes included:

- **Urinary Leakage:** Quantified as the total volume (mL) of drainage collected via the JP drain over the first 24 hours.
- **Renal Function:** Assessment of preoperative and 48-hour postoperative serum creatinine and BUN levels.
- **Postoperative Pain:** Measured on day one using the Visual Analogue Scale (VAS).
- **Safety:** Incidence of complications such as urinoma or ureteral stricture during the early follow-up period.

Follow-up protocol

Postoperative follow-up included clinical evaluation at 1 month, 3 months, 6 months, and annually thereafter. Renal ultrasound was performed at the 1- and 3-month visits to assess for hydronephrosis. The absence of ureteral stricture was determined clinically and via imaging. For patients with persistent hydronephrosis on ultrasound, symptoms suggestive of obstruction, or pre-existing renal impairment, further assessment with *computed tomography urography* (CTU) or *diuretic renal scintigraphy* (DRS) was performed to evaluate drainage and split renal function. Serum creatinine and BUN levels were monitored at each visit.

Statistical analysis

Data analysis was performed using the *Statistical Package for the Social Sciences* (SPSS), version 26.0 (IBM Corp., Armonk, NY, USA). Continuous variables, such as patient age, operative time, and laboratory values, were initially assessed for normality using the Shapiro-Wilk test to ensure they met the assumptions required for parametric testing. These variables are expressed as mean \pm standard deviation (SD). For comparisons between the sutured and sutureless cohorts, the independent samples t-test was utilized. Categorical data, including gender distribution, stone laterality, and the presence of comorbidities, were presented as frequencies and percentages. These were analyzed using the Pearson Chi-square test or Fisher's exact test, as appropriate, depending on the expected cell frequencies. To evaluate the impact of the surgical technique on renal function and systemic stability, the change (Δ) in serum creatinine, BUN, and hemoglobin from baseline to 48 hours postoperatively was calculated and compared using the independent t-test. All statistical tests were two-tailed, and a p-value of less than 0.05 was considered the threshold for statistical significance.

RESULTS

Baseline patient characteristics and stone parameters

A total of 60 patients were included in this comparative study, with 30 patients undergoing sutured laparoscopic ureterolithotomy (LU) and 30 patients undergoing the sutureless technique. As detailed in Table 1, there were no statistically significant differences between the two cohorts regarding baseline demographics. The mean age of the study population was 47.8 ± 15.6 years in the sutured group and 43.2 ± 16.1 years in the sutureless group ($p = 0.193$). Gender distribution was identical across both groups, with a male predominance of 76.7%. Clinical parameters including body weight ($p = 0.706$), height ($p = 0.564$), and the prevalence of comorbidities

Variable	Sutured group (n = 30)	Sutureless group (n = 30)	P-value
Age (years), Mean ± SD	47.8 ± 15.6	43.2 ± 16.1	0.193
Gender (Male), n (%)	23 (76.7%)	23 (76.7%)	0.999
Body Weight (kg), Mean ± SD	75.3 ± 10.1	74.2 ± 11.2	0.706
Height (cm), Mean ± SD	169.1 ± 7.2	170.2 ± 6.8	0.564
Comorbidities, n (%)			
- Hypertension	6 (20.0%)	4 (13.3%)	0.488
- Diabetes Mellitus	3 (10.0%)	2 (6.7%)	0.640
Stone Characteristics			
- Mean Stone Size (mm)	14.2 ± 2.6	13.8 ± 3.1	0.551
- Laterality (Right/Left)	16/14	15/15	0.802
- Hydronephrosis (Mild/Mod/Sev)	8/12/10	9/11/10	0.841

Table 1.
Baseline demographic and clinical characteristics of the study population.

such as hypertension ($p = 0.488$) and diabetes ($p = 0.640$) were well-balanced between the groups. Furthermore, stone characteristics – including mean size (14.2 mm vs. 13.8 mm; $p = 0.551$), laterality ($p = 0.802$), and the severity of preoperative hydronephrosis ($p = 0.841$) – showed no significant variations, ensuring a homogenous baseline for surgical comparison.

Prior treatment history and preoperative status

Among the 30 patients in the sutured group, prior treatments included failed ESWL in 4 (13.3%), failed ureteroscopy (URS) in 2 (6.7%), and medical expulsive therapy (MET) alone in 24 (80.0%). Corresponding figures for the 30 patients in the sutureless group were 5 (16.7%), 1 (3.3%), and 24 (80.0%), respectively ($P = 0.899$ for ESWL; $P = 0.554$ for URS; $P = 0.999$ for MET; all comparisons not statistically significant). Preoperative treated urinary tract infection was documented in 3 (10.0%) and 2 (6.7%) patients in the sutured and sutureless groups, respectively ($P = 0.640$; not statistically significant).

Primary surgical and perioperative outcomes

The surgical outcomes are summarized in Table 2. A key

finding of our study was the significant reduction in operative time for the sutureless cohort, which averaged 2.2 ± 0.3 hours compared to 2.7 ± 0.4 hours in the sutured group ($p < 0.001$). Regarding postoperative healing, the mean duration of internal stenting was statistically longer in the sutureless group (17.7 ± 4.4 days) than in the sutured group (16.1 ± 5.2 days; $p = 0.050$). While this difference reached the threshold for statistical significance, it was considered clinically marginal in the context of overall recovery.

In terms of safety and postoperative complications, the volume of urinary leakage – measured via the Jackson-Pratt drain over the first 24 hours – was slightly higher in the sutureless group (72.1 ± 28.4 mL) than in the sutured group (64.9 ± 25.1 mL); however, this trend did not reach statistical significance ($p = 0.066$). Importantly, no cases of urinoma formation were observed in either group. Additionally, the length of hospital stay ($p = 0.672$) and postoperative pain scores ($p = 0.448$) were comparable between the two techniques.

Postoperative laboratory indices and renal function

Comparative laboratory data are presented in Table 3.

Outcome	Sutured group (n = 30)	Sutureless group (n = 30)	P-value
Operative Time (hours)	2.7 ± 0.4	2.2 ± 0.3	<0.001
Stent Removal Time (days)	16.1 ± 5.2	17.7 ± 4.4	0.050
Hospital Stay (days)	3.0 ± 0.8	2.9 ± 0.7	0.672
Urinary Leakage (mL)*	64.9 ± 25.1	72.1 ± 28.4	0.066
Postoperative Pain (VAS Score)	3.2 ± 1.1	3.0 ± 0.9	0.448
Complications (Clavien-Dindo ≥ II)	0 (0%)	0 (0%)	-

*Measured as total volume from the Jackson-Pratt drain over the first 24 hours.

Table 2.
Primary surgical and perioperative outcomes.

Parameter	Sutured group (n = 30)	Sutureless group (n = 30)	P-value
Postoperative Hemoglobin (g/dL)	13.9 ± 0.9	13.8 ± 0.9	0.733
Postoperative BUN (mg/dL)	16.8 ± 3.7	16.4 ± 5.4	0.335
Postoperative Creatinine (mg/dL)	1.3 ± 0.3	1.2 ± 0.3	0.309
Δ Hemoglobin (g/dL)	0.1 ± 0.2	0.1 ± 0.2	0.442
Δ BUN (mg/dL)	1.3 ± 2.8	1.6 ± 2.1	0.648
Δ Creatinine (mg/dL)	0.3 ± 0.3	0.2 ± 0.3	0.494

Δ (Delta) represents the mean change from baseline to 48-hour postoperative values. BUN: Blood Urea Nitrogen.

Table 3.
Comparison of preoperative and postoperative laboratory indices.

Variable	Sutured group (n = 30)	Sutureless group (n = 30)	P-value
Median Follow-up (years)	3.2 (3.0-3.5)	3.4 (3.1-3.6)	0.420
Late Ureteral Stricture, n (%)	0 (0%)	0 (0%)	0.999
Stone Recurrence, n (%)	3 (10.0%)	2 (6.7%)	0.640
Secondary Interventions, n (%)	1 (3.3%)	1 (3.3%)	0.999
Chronic Flank Pain, n (%)	1 (3.3%)	0 (0%)	0.313

Table 4.
Long-term follow-up and comparative safety profile.

Postoperative renal function remained stable in both groups, with no significant differences noted in serum creatinine ($p = 0.309$) or *blood urea nitrogen* (BUN) levels ($p = 0.335$). The change (Δ) in hemoglobin levels from baseline was also negligible and statistically similar between the sutured and sutureless cohorts ($p = 0.442$), suggesting that the choice of ureteral closure does not significantly impact perioperative blood loss or systemic physiological stability.

Long-term follow-up and safety outcomes

The long-term safety and functional success of the two techniques were evaluated over a median follow-up period of 3.3 years (range: 3.0-3.6 years). During this extended observation window, there were no reported cases of late-onset ureteral strictures in either cohort. All patients underwent renal ultrasound during follow-up. For the 5 patients (2 in the sutureless group and 3 in the sutured group) with concerning findings (persistent hydronephrosis or symptoms), further imaging with CT urography confirmed the absence of functional obstruction; diuretic renal scintigraphy was not performed given definitive negative structural findings, though it remains the reference standard for equivocal functional assessment. Regarding stone recurrence, a total of five cases were identified during the follow-up period: two (6.7%) in the sutureless group and three (10.0%) in the sutured group. This difference was not statistically significant ($p = 0.640$) (Table 4).

DISCUSSION

This study sought to evaluate the clinical efficacy and safety of sutureless versus conventional sutured transperitoneal LU for the management of large proximal ureteral stones. Our primary findings indicate that the sutureless technique significantly reduces operative time without compromising renal function or increasing the risk of major complications. By omitting the technically demanding phase of intracorporeal suturing, surgeons can enhance operative efficiency while relying on the innate regenerative capacity of the ureteral mucosa.

Laparoscopic ureterolithotomy is established as a definitive minimally invasive procedure for large or impacted proximal ureteral stones (16). The transperitoneal approach affords a larger working space and superior visualization of anatomical landmarks, facilitating complex stone retrieval and dissection, but carries increased risks of visceral organ injury, peritoneal contamination through urinary leakage, and postoperative ileus (17, 18). In contrast, the retroperitoneal approach presents a confined workspace but significantly reduces the risk of intra-abdominal injuries and peritoneal contamination, result-

ing in fewer postoperative complications and faster recovery times (19). Our preference for the transperitoneal route aligns with these advantages, although case-specific factors such as previous retroperitoneal surgery or nephrostomy tube placement necessitate a transperitoneal approach. Importantly, the ideal anatomical location for laparoscopic ureterotomy is between the renal lower pole and the iliac vessels, where minimal dissection is required. The detailed surgical technique, including colon mobilization for ureter identification and standardized drain placement, as described in our methods, contributes to the reproducibility and safety of both approaches.

The debate regarding the necessity of ureterotomy suturing in LU continues to evolve. Suturing provides immediate anatomical closure and offers theoretical reinforcement of the anastomosis, which may reduce early urinary leakage. However, contemporary evidence suggests that non-sutured ureterotomy closure – when combined with optimal ureteral stenting and careful retroperitoneal drainage – does not significantly increase postoperative urinary leakage or related complications (6, 9, 20). In this study, there was no statistically significant difference in postoperative leaks between the non-sutured and sutured groups. Our findings are consistent with previous reports indicating that postoperative leaks observed in the absence of suturing are predominantly transient, often attributed to mucosal edema and localized inflammation impairing early tissue apposition rather than surgical technique failure (21). Keeley *et al.* emphasized that in the absence of suturing, adequate decompression and drainage can safely manage such leaks, providing a rationale for the selective adoption of sutureless techniques in appropriate patients (20).

Suturing of the ureterotomy provides immediate structural reinforcement but increases operative time, technical complexity, and the risk of tissue ischemia due to prolonged manipulation. Conversely, non-suturing reduces operative duration and simplifies the procedure but may predispose to early leakage related to tissue edema and inflammation (6, 20, 22). In our study, there was a statistically significant difference in operative time between the non-sutured and sutured groups, with longer durations observed in the sutured group, aligning with findings from previous studies. The consistent use of ureteral stents, as demonstrated in our series and supported by prior research, acts as an internal scaffold that promotes mucosal approximation and healing, effectively reducing leakage complications (6, 12, 19, 23, 24). However, as known to all, the operative time is directly related with many variables such as the types of approach, surgeon's experience, individual differences of patients, and the different equipment used. Therefore, balancing operative

efficiency with anastomotic security remains central in technique selection, ideally tailored to patient factors and surgeon expertise.

Additional insights can be gained from related laparoscopic procedures. In pyeloplasty, continuous suturing techniques – especially with advancements such as barbed sutures – have contributed to shorter operative times and high success rates, reducing postoperative urinary leakage without compromising anastomotic integrity (25). Partial nephrectomy approaches utilizing sutureless or minimally sutured techniques, supplemented by hemostatic agents and parenchymal compression, have demonstrated reductions in warm ischemic time, blood loss, and hospital stay without increasing the risk of urinary fistula or renal dysfunction (11). These procedures exemplify how tailoring suturing strategies to anatomical and procedural complexities can optimize outcomes. Such evidence supports our findings that sutureless ureterotomy expedites the procedure, with prolonged stenting necessary to ensure safe ureteral healing.

The lack of a significant difference in the length of hospital stay between the two groups indicates that this outcome is likely influenced by a broader set of factors beyond the suturing technique alone. Variables such as postoperative pain control, return of bowel function, patient comorbidities, and overall recovery trajectory may play a more dominant role in determining discharge readiness than the specific method of ureterotomy closure. This suggests that while technical modifications can optimize certain intraoperative metrics, they may not singularly dictate the overall postoperative recovery pace (26).

A significant complication associated with laparoscopic ureterolithotomy is ureteral stricture, which has been documented in approximately 15-20% of cases in various series (2, 24, 26). Although the exact etiologies of postoperative ureteral strictures remain uncertain, proposed mechanisms include overly tight suturing of the ureterotomy site, leading to ischemia of the ureteral wall and subsequent stenosis (27). Additionally, prolonged postoperative urinary drainage, which can result in retroperitoneal fibrosis, has been suggested as another potential cause of ureteral narrowing (24, 28). Notably, no ureteral strictures occurred in our cohort; while functional assessment via diuretic renal scintigraphy was not performed given negative CT urography findings, longer follow-up duration is recommended to definitively exclude late stricture formation.

Consistent with the high success rates reported in the literature, all patients in our study achieved an immediate 100% stone-free rate (29). While laparoscopic lithotripsy is known to surpass the stone-free rates of ureterorenoscopy for large proximal stones, long-term monitoring is essential (30). Our follow-up revealed a minimal recurrence rate – 6.7% (n = 2) in the sutureless group and 10.0% (n = 3) in the sutured group (p = 0.640). This is consistent with the natural history of urolithiasis and demonstrates that the choice of ureteral closure does not impact long-term stone-free survival.

Clinical implications

The clinical implications of our findings favor a nuanced, patient-centered approach. Reducing operative time

through sutureless techniques enhances surgical throughput and resource utilization – factors of increasing importance in modern healthcare. However, the slightly longer duration of stenting required for sutureless cases must be balanced against patient comfort and stent-related morbidity. Our study contributes robust evidence to the field, demonstrating that sutureless transperitoneal LU is a feasible, safe, and efficient alternative for managing complex proximal ureteral stones when performed by an experienced surgical team.

Study limitations

While this study provides robust comparative data on the sutureless technique, several limitations must be considered when interpreting the results. First, the retrospective nature of the analysis and the specific sample size may introduce inherent selection bias. Although our cohort was statistically powered to detect significant differences in the primary endpoint of operative time, it may be less sensitive in identifying rare, low-frequency postoperative complications.

DECLARATIONS

Ethical approval and consent for participate: This study was approved by the Ethics Committee of Shiraz University of Medical Sciences, Shiraz, Iran (Approval No. IR.SUMS.MED.REC.1403.546). All procedures performed were in accordance with the ethical standards of the institutional and national research committees and with the 1964 Helsinki Declaration and its later amendments or comparable ethical standards.

Availability of data and material: The data supporting this study's findings are available from the corresponding author upon reasonable request.

Competing interests: The authors declare that they have no known competing financial interests or personal relationships that could have influenced the work reported in this paper.

Funding: This research did not receive any specific grant from funding agencies in the public, commercial, or not-for-profit sectors.

Authors' contributions: Seyed Ali Eslahi, Faisal Ahmed; Data Curation: Iman Shamohammadi, Ali Akbarian, Ali Adib.; Formal Analysis: Seyed Hossein Hosseini, Mazen Karama; Writing – Original Draft: Seyed Ali Eslahi, Iman Shamohammadi; Writing – Review & Editing: Faisal Ahmed, Mazen Karama, Seyed Hossein Hosseini.

All authors reviewed and approved the final manuscript for publication.

Acknowledgments: None.

Generative AI and AI-Assisted Technologies in the Writing Process: During the preparation of this work, the authors utilized Gemini AI for the sole purposes of proofreading and linguistic refinement. This technology was employed to improve the grammatical accuracy, clarity, and overall readability of the manuscript.

The authors explicitly declare that the AI was not used to generate original data, interpret clinical findings, or formulate the intellectual conclusions presented in this study. Following the AI-assisted editing process, the authors meticulously reviewed and edited the content to ensure technical accuracy and take full responsibility for the final integrity of the published work.

Second, although the study was conducted within an academic tertiary referral center involving urologic residents and laparoscopic fellows, all procedures were performed or strictly supervised by a single experienced surgeon (Prof. Ali Eslahi). While this "single-surgeon" model is a significant methodological strength – as it eliminates inter-operator variability and ensures a highly standardized technical approach – it may limit the generalizability of the results to centers with different levels of laparoscopic expertise or training protocols.

Third, the transperitoneal approach utilized in this study provides excellent visualization but may differ in postoperative recovery profiles compared to the retroperitoneal approach used in other centers. Furthermore, while our 3.3-year median follow-up is robust for assessing long-term patency, continued monitoring is necessary to definitively rule out late-onset obstructive sequelae. Finally, future prospective, multi-center randomized controlled trials are warranted to further validate these findings and establish the sutureless approach as a global standard of care for large proximal ureteral stones.

CONCLUSIONS

Laparoscopic ureterolithotomy is a highly effective and safe method for managing complex proximal ureteral stones. Our comparative analysis demonstrates that a sutureless transperitoneal approach offers a clear advantage in reducing operative time without compromising short-term renal safety or increasing the risk of significant complications like urinoma.

Although the sutureless technique may necessitate a slightly longer duration of internal stenting to facilitate healing, the clinical outcomes are comparable to traditional sutured closure. Ultimately, the choice between these two methods should be a personalized decision, guided by the patient's anatomy, the surgeon's technical comfort, and a balanced consideration of operative efficiency versus the minor morbidity of extended stenting.

REFERENCES

- Zhang L, Zhang X, Pu Y, et al. Global, Regional, and National Burden of Urolithiasis from 1990 to 2019: A Systematic Analysis for the Global Burden of Disease Study 2019. *Clin Epidemiol.* 2022; 14:971-83.
- Bai Y, Tang Y, Deng L, et al. Management of large renal stones: laparoscopic pyelolithotomy versus percutaneous nephrolithotomy. *BMC Urol.* 2017; 17:75.
- Zahirian Moghadam T, Pourfarzi F, Mohseni Rad H, Zandian H. Kidney stones among Iranian adults: Prevalence and socioeconomic inequality assessment in a cohort-based cross-sectional study. *Health Sci Rep.* 2022; 5:e877.
- Parks JH, Coe FL. The financial effects of kidney stone prevention. *Kidney Int.* 1996; 50:1706-12.
- Meria P, Milcent S, Desgrandchamps F, et al. Management of pelvic stones larger than 20 mm: laparoscopic transperitoneal pyelolithotomy or percutaneous nephrolithotomy? *Urol Int.* 2005; 75:322-6.
- Tena González Méndez G, García-Escobar JC, Jiménez-Cisneros E, et al. The role of laparoscopic surgery in the management of uri-

- nary lithiasis in the era of endourology in Mexico. *Revista Mexicana de Urología.* 2024; 84:1-12.
- Simforoosh N, Aminsharifi A. Laparoscopic management in stone disease. *Curr Opin Urol.* 2013; 23:169-74.
- Bayar G, Tanriverdi O, Taskiran M, et al. Comparison of laparoscopic and open ureterolithotomy in impacted and very large ureteral stones. *Urol J.* 2014; 11:1423-8.
- Kijivkai K. The role of laparoscopic surgery for renal calculi management. *Ther Adv Urol.* 2011; 3:13-8.
- Al-Hunayan A, Abdulhalim H, El-Bakry E, et al. Laparoscopic pyelolithotomy: is the retroperitoneal route a better approach? *Int J Urol.* 2009; 16:181-6.
- Zhang F, Gao S, Zhao Y, et al. Comparison of Sutureless and Conventional Laparoscopic Partial Nephrectomy: A Propensity Score-Matching Analysis. *Front Oncol.* 2021; 11:649356.
- Abdel Raheem A, Alowidah I, Hagra A, et al. Laparoscopic ureterolithotomy for large proximal ureteric stones: Surgical technique, outcomes and literature review. *Asian J Endosc Surg.* 2021; 14:241-9.
- Singh V, Sinha RJ, Gupta DK, et al. Transperitoneal versus retroperitoneal laparoscopic ureterolithotomy: a prospective randomized comparison study. *J Urol.* 2013; 189(3):940-5.
- Hu H, Xu L, Wang S, et al. Ureteral stricture formation after removal of proximal ureteral stone: retroperitoneal laparoscopic ureterolithotomy versus ureteroscopy with holmium: YAG laser lithotripsy. *PeerJ.* 2017; 5:e3483.
- Skrepetis K, Doumas K, Siafakas I, Lykourinas M. Laparoscopic versus open ureterolithotomy. A comparative study. *Eur Urol.* 2001; 40:32-6.
- Garg M, Singh V, Sinha RJ, et al. Prospective Randomized Comparison of Open versus Transperitoneal Laparoscopic Ureterolithotomy: Experience of a Single Center from Northern India. *Curr Urol.* 2013; 7:83-9.
- Khalil M, Omar R, Abdel-Baky S, Mohey A, Sebaey A. Laparoscopic ureterolithotomy; which is better: Transperitoneal or retroperitoneal approach? *Turk J Urol.* 2015; 41:185-90.
- Bove P, Micali S, Miano R, et al. Laparoscopic ureterolithotomy: a comparison between the transperitoneal and the retroperitoneal approach during the learning curve. *J Endourol.* 2009; 23:953-7.
- Al-Sayyad A. Laparoscopic transperitoneal ureterolithotomy for large ureteric stones. *Urol Ann.* 2012; 4:34-7.
- Keeley FX, Gialas I, Pillai M, et al. Laparoscopic ureterolithotomy: the Edinburgh experience. *BJU Int.* 1999; 84:765-9.
- Nouira Y, Kallel Y, Binous MY, et al. Laparoscopic retroperitoneal ureterolithotomy: initial experience and review of literature. *J Endourol.* 2004; 18:557-61.
- Feyaerts A, Rietbergen J, Navarra S, et al. Laparoscopic ureterolithotomy for ureteral calculi. *Eur Urol.* 2001; 40:609-13.
- El-Moula MG, Abdallah A, El-Anany F, et al. Laparoscopic ureterolithotomy: our experience with 74 cases. *Int J Urol.* 2008; 15:593-7.
- Sahin S, Aras B, Eksi M, et al. Laparoscopic Ureterolithotomy. *JSLs.* 2016; 20:e2016.00004.
- Ramalingam M, Murugesan A, Senthil K, Pai MG. A comparison of continuous and interrupted suturing in laparoscopic pyeloplasty. *JSLs.* 2014; 18:294-300.

26. Tonyali S, Yilmaz M, Tzelvels L, et al. Predictors of Ureteral Strictures after Retrograde Ureteroscopic Treatment of Impacted Ureteral Stones: A Systematic Literature Review. *J Clin Med.* 2023; 12:3603.
27. Aminsharifi A, Hosseini MM, Khakbaz A. Laparoscopic pyelolithotomy versus percutaneous nephrolithotomy for a solitary renal pelvis stone larger than 3 cm: a prospective cohort study. *Urolithiasis.* 2013; 41:493-7.
28. Darwish AE, Gadelmoula MM, Abdelkawi IF, et al. Ureteral stricture after ureteroscopy for stones: A prospective study for the incidence and risk factors. *Urol Ann.* 2019; 11:276-81.
29. Basiri A, Tabibi A, Nouralizadeh A, et al. Comparison of safety and efficacy of laparoscopic pyelolithotomy versus percutaneous nephrolithotomy in patients with renal pelvic stones: a randomized clinical trial. *Urol J.* 2014; 11:1932-7.
30. Wang X, Li S, Liu T, et al. Laparoscopic pyelolithotomy compared to percutaneous nephrolithotomy as surgical management for large renal pelvic calculi: a meta-analysis. *J Urol.* 2013; 190:888-93.

Correspondence

Seyed Ali Eslahi

alieslahi@yahoo.com

Seyed Hossein Hosseini

Shhosseini_6687@yahoo.com

Iman Shamohammadi

imanshamohammadi@yahoo.com

Ali Akbarian

akbarian2736@gmail.com

Ali Adib

Aliadibmail@gmail.com

Department of Urology, Faculty of Medicine, Shiraz University of Medical Sciences, Shiraz, Iran

Mazen Karama

Uromaz@gmail.com

Urology Department, Faculty of Medicine, Aden University, Aden, Yemen

Faisal Ahmed (Corresponding Author)

Fmaaa2006@yahoo.com

Department of Urology, Ibb University, Ibb, Yemen.